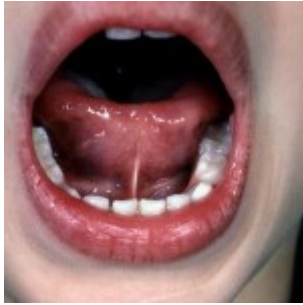

# Tongue Tie – Release by Laser Surgery

April 26, 2008 by Dr Paulose



## TONGUE TIE

### Introduction

**Ankyloglossia** or **tongue-tie**, occurs in patients whose lingual frenum is short and tight resulting in decreased mobility of the tongue.

Tongue-tie is generally diagnosed in childhood and symptoms include: Interference with feeding in infants. There are infants who cannot suck toddlers who cannot chew, children who cannot lick ice creams, and children and adults who are disadvantaged by their poor speech.

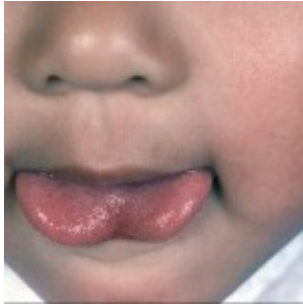Tongue-tie is more commonly found in boys (60%) and there will often be other family members who have had this problem. The most immediate impact of tongue-tie is on the baby's ability to breastfeed effectively. There may be an affect on ongoing oral hygiene. The effect of tongue-tie on speech development remains controversial.

You can test for a tongue tie by having your child stick out his tongue. If he can't do so or if when he does so the tip is held back – looking like a sort of W shape at the tip rather than a V shape – then he probably is tongue tied.

The incidence of ankyloglossia reported in the scientific literature varies from 0.02% to 4.8%.

This decreased tongue mobility can be associated with speech problems in children. Specifically, a child may exhibit difficulty with the articulation of the sounds L, R, T, D, N, Th, Sh, and Z.

### Why tongue tie?



It is a real medical condition and has its own typical problems and presentation. Symptoms can be mild or severe, and where no difficulties are caused no intervention is needed. Where problems exist, it can be diagnosed, assessed, and successfully treated. It is not well known – although the expression ‘tongue tied’ is generally used to mean ‘unable to speak’.

The frenum is a remnant of tissue that was part of the facial structure of the infant during early pregnancy. Usually it disappears or reduces to a very slight membrane which is elastic and does not limit the tongue in its movements or disrupt function. Similar webs of tissue can also occur joining the cheeks or lips to the gums and these – like a tongue tie – also can be released surgically. When the lingual frenum does cause problems it is because tightness, thickness or width of the frenum affects the function of the tongue in various ways. There is a very strong tendency for tongue tie to run in families, and it is more common in boys.

#### **Who should diagnose it?**

Tongue tie may be diagnosed by ENT (ear, nose and throat) surgeons, dentist or speech therapist or a pediatrician.

#### **Infants**

Tongue-tie can interfere with a baby’s ability to suckle efficiently at the breast. This may lead to nipple pain and trauma, poor breast milk intake and a decrease in milk supply over time. Inability to breastfeed successfully in the presence of a tongue tie can cause a variety of challenges for the infant, the mother and the family.

Feeding difficulties may be a reason to consider early surgery to cut the lingual frenulum and loosen the tongue.

#### **Children**

Children with a tongue tie have to contend with difficulties which may only be discovered as they grow older. Problems start with speech at 12 to 18 months. Some older children or teenagers may notice that the frenum under their tongue becomes stuck between their front teeth, or that they can’t stick their tongue out as far as their friends can.

#### **For Adults**

The areas of difficulty spread to include social and domestic situations, self-esteem, the work environment, and dental health. Adults receiving dentures may need a frenectomy if the position of a frenum will interfere with the proper fit of the denture.

Inability to kiss with tongue out. Main concern for youngsters.

## **Consequences of Untreated Tongue Tie**

### **Cosmetic Appearance**

On first observing a neonate with tongue tie, the cosmetic appearance of the tongue and the tie will stand out. The tongue may look small, rounded and indented in the midline with a heart-shaped look. If the frenum does not reach the lingual margin this typical heart shape may not be apparent, although function of the tongue may still be significantly impaired.

As the child grows older, the appearance changes and the tongue may look square, or bifid, or thickened and too large for the mouth, so that it curls up at the sides. The tie itself can vary from a thin elastic membrane to a thickened, white non-elastic tissue. The tie or frenum may extend to the lingual margin causing notching, or spread along the floor of the mouth in a fan shape reaching towards the incisors and causing discomfort or actual pain on activity.

Salivary profusion due to inadequate coordination of swallowing during speech becomes both visually and auditorily obvious. Habits of mouth breathing, aerophagia and forward tongue position become entrenched, and are easily noticed and less excused in the teenager or adult person.

The appearance of both the tie and the tongue generally becomes more conspicuous and even ugly, as the child grows older. V-shaped notch at the tip of the tongue, Inability to protrude the tongue past the upper gums, Inability to touch the roof of the mouth

### **Speech**

In some children, tongue-tie may also cause speech defects, especially articulation of the sounds – l t r d th

The tongue is remarkably able to compensate, however, and many children have no speech impediments due to tongue tie.

Clarity in rapid speech is almost always impossible for a tongue-tied person to achieve.

### **Emotional Factors**

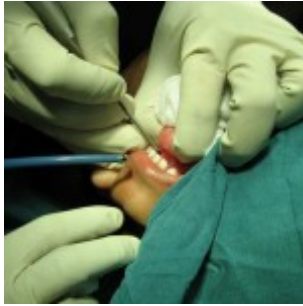There will be negative repercussions on self esteem and confidence and emotional or behavioral problems soon follow.

“Tongue tie patients live in a state of stress”.

It hardly needs to be stressed that if our verbal messages are not received and understood, we can become isolated from our fellows or overly dependent on interpreters. Both children and adults can then lack self confidence, and sometimes, fail to achieve the success that brings financial and social comfort.

## **How to Release tongue tie?**

### **Surgical Options**



Lingual frenotomy is often performed on newborns and neonates with tongue-tie to enable them to latch and suckle. Lingual frenotomy is sometimes referred to as “tongue clipping”. It is done with a local anesthetic.

Children should be assessed by a speech-language pathologist prior to tongue tie surgery. Some require pre-operative exercises, and most require post-operative exercises under a speech-language pathologist’s supervision.

### **How clipping the short frenulum is done**

Clipping a short frenulum is a quick and painless procedure. It can be done in doctor’s office. A newborn baby has a very thin frenulum that is easy to clip and usually bleeds very little or not at all. The doctor holds the tip of the tongue with a piece of gauze and uses scissors to clip the frenulum back to where it joins the base of the tongue.

Tongue clipping is a greatly disputed procedure among parents, physicians, lactation consultants, and speech pathologists. Some feel that the procedure is not done as frequently as necessary, and that children are required to wait until speech problems develop, before the frenulum is clipped. Some doctors are reluctant to do this procedure, because most tight tongues loosen with time and they may be uninformed about how a baby uses his tongue to get milk out of the breast. You can also refer to an oral surgeon, pediatric dentist, or ear, nose, and throat specialist about getting the baby’s tongue clipped.

However, when ankyloglossia is associated with foreshortening of the genioglossus muscle, as often occurs, merely snipping the lingual frenum may not allow free and coordinated movement of the tongue sufficient for the demands of a gradually growing speech and language structure. As a result, further surgery may legitimately be needed later. Therefore, the possibility that re-evaluation of the situation might become appropriate later, should be emphasized.

### **Surgery in Hospital**

Surgeons generally operate at the earliest at 6 months, when the baby is felt to be better able to handle a general anaesthetic. This postponement of surgery has the disadvantage of prolonging the period of feeding difficulty and strengthening habits of abnormal tongue movement.

The presence of important blood vessels in the area makes it preferable for the patient to be anaesthetized, to avoid the possibility of accidentally cutting these vessels and causing excessive bleeding.

### **Surgery under a General Anesthetic**

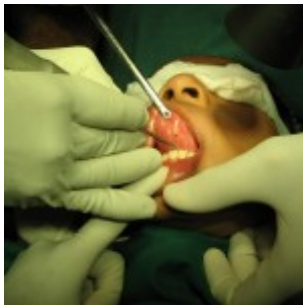
The release of a tongue-tie involves the surgeon placing a finger and thumb under the baby's tongue to gain clear access to the frenulum. The frenulum is released with a small pair of sterile scissors.

Surgery in hospital usually involves a half-day stay, fasting prior to the operation, approximately 4 minutes under a general anesthetic, and soluble stitches along the incision. There is usually discomfort until healing is complete and this may take approximately 10 days, after which speech therapy may be commenced. The procedure is very safe and there are no contra-indications.

Tongue tie surgery (lingual frenectomy) involves more than just a simple clipping or a quick snip, but more involved tissue resection under general anesthetic. It is therefore not recommended unless there is a good (speech, dental or other) justification for doing it.

Lingual frenectomy and lingual frenotomy are different procedures.

### **Laser Surgery**

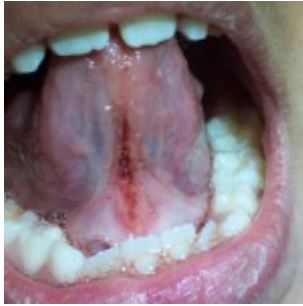

### **Sublingual Frenectomy Using Co2 laser**

Very effective and minimally invasive procedure with immediate improvement in speech.

The term laser is an abbreviation for light amplification by stimulated emission of radiation. Many lasers are available, including CO<sub>2</sub>, Nd:YAG, Each of these lasers exhibits specific properties depending on their position in the electromagnetic spectrum.

Wavelength specific laser protective glasses were placed on the patient and everyone in the treatment room. The tissue was dried with gauze and Xylocainne Gel was applied to the lingual frenum for 5 minutes.



### **Advantages of using laser**

This relatively new option is suitable for neonates, older children and adults. No general anesthetic is used, but an analgesic gel might be applied. The procedure is very quick, taking only 2 to 3 minutes to perform, but some cooperation from the patient in keeping still is required.

There is virtually no bleeding, no pain, no risk of infection and the healing period can be as short as 2 hours.

It is best to have this procedure performed by a laser surgeon.

### **Management and Speech Therapy**

Speech symptoms in tongue-tied patients vary enormously, and speech therapy without surgical intervention in such cases is at best a lengthy process, and at worst, expensive, frustrating for patient and therapist, and unsuccessful. Following surgery, speech therapy to address areas of difficulty identified in the assessment process should begin as soon as possible after healing is complete.

Articulation of specific sounds may be consistently defective, particularly where pronunciation requires lingual elevation, as in T, D, and N and these errors can be addressed with conventional therapy exercises. However, it is more important to address issues such as the ability of the tongue to transfer from one articulatory posture to another.

### **Post-operative exercises**

1. Stretch your tongue up towards your nose, then down towards your chin. Repeat.
2. You can vary the exercise above and make it more interesting by putting a dab of food in various positions above the top lip, to be retrieved with the tongue tip
3. Open your mouth widely. Touch your big front teeth with your tongue with your mouth still open.
4. Look in the mirror. Still with your mouth open wide, say dar-dar-dar, now say nar-nar-nar, now say tar-tar. Look in the mirror to see what your tongue is doing. Can you FEEL where it is?
5. Lick your whole top lip from one side to the other.
6. Poke your tongue out as far as it will go.
7. Now see if you can make your top lip fat without opening your mouth.
8. Can you go in-out-in-out-in-out with your tongue

### **Conclusions**

Parents who blame the tongue tie primarily for the child's feeding or speech problems

are no longer thought to be either neurotic or fooling themselves. It is being increasingly accepted by disciplines associated with infants, children and adults with tongue tie that there is now no place for 'wait and see' policies when the tongue tie has been identified and diagnosed as abnormal, and early intervention is the optimal form of management.