when 9 months is a lifetime

Photo: Red Huber/Orlando Sentinel

Children's Advanced Fetal Care Center gives expectant parents a reason to hope

For most families, the 40 weeks of pregnancy are a time of nervous anticipation. As the expectant mother's belly grows, so do the dreams for the future of the unborn child, the hope that the pregnancy and delivery will be successful, and the wishes for the child's good health.

But not all pregnancies go according to plan, and in cases where fetal birth defects put the pregnancy, delivery, and life of the baby and mother at risk, nearly 300 pregnant mothers-to-be have turned for help to the Advanced Fetal Care Center (AFCC) at Children's Hospital Boston. One of only four comprehensive fetal care centers in the country—and the only one in New England—the AFCC brings together pediatric specialists from throughout the hospital to diagnose everything from the potentially fatal to the hopefully simple.

"This program puts advanced imaging techniques in the hands of experienced diagnostic specialists to provide crucial information to parents having difficult pregnancies so they can make decisions about their unborn baby," says Rusty Jennings, MD, director of the AFCC. "From the parents' point of view, in one day we give them the information they need to decide what to do next."

Doctors and nurses have at their disposal state-of-the-art diagnostic testing that can be used throughout the pregnancy to monitor the progression of an anomaly. For many families, this is all the intervention that is necessary, but for more complex patients, pediatric specialists provide a number of options. These include delivering the baby and placing him or her on an advanced heart-lung bypass machine until surgeons can correct the problem; operating on the baby during delivery; and partially removing the baby for surgery and returning him or her to the womb to finish developing.

"At-risk pregnancies require an immense amount of support every step of the way—this is what we strive to provide," says AFCC nurse practitioner Luanne Nemes, RN, MS, PNP.

For Dawn and Jeff Methven, a couple from Florida, support from the AFCC gave them something they may otherwise have been without during Dawn's pregnancy: hope. They had been trying to get pregnant for three years when they found out in December 2001 that a baby boy they would name Dylan was expected in September 2002. They prepared the room in their

The Advanced Fetal Care Center

The AFCC brings together pediatric specialists in fetal surgery, fetal imaging and diagnosis, neonatal care, genetics, anesthesiology, cardiology, cardiovascular surgery, otolaryngology, urology, neurology and other areas.

Specialists treat conditions ranging from heart defects and congenital diaphragmatic hernia (see sidebar on pg. 27), to spina bifida (abnormal development of the back bones and spinal cord) and hypoplastic left heart syndrome (a combination of several abnormalities of the heart and great blood vessels).

The goal of the AFCC is to provide the most accurate diagnosis and the best treatment options for each child before and after birth, while supporting the entire family.

new house that would be the nursery, and thought about how their two miniature dachshunds would adapt to their new brother. Although they were anxious, they were ready to be parents.

But their plans suddenly changed when Dawn went to her 27-week obstetric appointment, and ultrasound pictures showed a mass growing on Dylan's tiny head. Doctors told Dawn and Jeff that no one in Orlando had ever seen anything like it. The sickle-shaped mass was half the size of his head and was drawing so much blood to itself that it was causing a strain on Dylan's tiny heart. "It was more demanding than an organ would be," says Dawn.

Without an immediate diagnosis, Jeff and Dawn were confronted with the fact that Dylan, for whom they had waited so long, could die. Continuing to hope after trying for so long to get pregnant, the Methvens searched on.

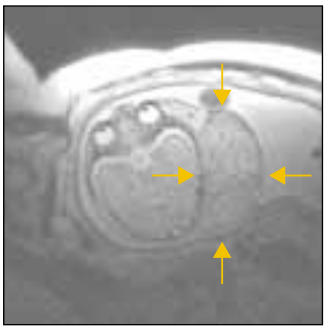

Fetal MRI showing the mass hugging the side of Dylan's skull.

A pediatric surgeon Dawn and Jeff saw in Orlando had trained under Steven Fishman, MD, co-director of Children's world-renowned Vascular Anomalies Center (VAC). He suggested that the AFCC was the best place for them to go.

So in June, Dawn and Jeff made their way north, where AFCC specialists in surgery, neurology, radiology and cardiology worked together to diagnose the mass connected to Dylan's head.

Dawn underwent a battery of tests so the specialists would have the images and information they needed to make decisions. First, she had an ultrasound and fetal magnetic resonance imaging (MRI) with Carol Barnewolt, MD, and Judy Estroff, MD, co-directors of Fetal Imaging at Children's.

These advanced technologies allowed pediatric radiology specialists to see the fetus from many different angles, and to view Dylan's head, internal organs and body in three-dimensional cross-sections. "From these high resolution images we can get a very accurate picture of how the baby is developing, and see the size and shape of abnormalities such as Dylan's," says Barnewolt.

She and Estroff then consulted Patricia Burrows, MD, chief of the Division of Interventional Radiology, who specializes in the diagnosis and treatment of rare vascular anomalies.

Based on Burrows' opinion and all the information they had collected, the care team that now included John Mulliken, MD, co-director of the VAC, laid out three possible diagnoses. The first was that the mass attached to Dylan's head was a type of tumor, known as a fibrosarcoma, that would need to be treated with chemotherapy and most likely surgery. The second was that the mass was a potentially life-threatening growth called an arterio-venous malformation, or AVM. AVMs often become so engorged with blood that delivery becomes dangerous because if the mass ruptures, the excessive bleeding could be fatal. The third possibility was that it was a congenital hemangioma, a

Photo: Roberto Gonzalez/Orlando Sentinel

Carol Barnewolt, MD (right), discusses Dylan's fetal ultrasound and MRI with (l-r) nurse practitioner Julie Iglesias, PNP (sitting), Jeff and Dawn Methven, Steven Fishman, MD, and Judy Estroff, MD.

rare oversized birthmark that goes away on its own in the first year of life, but needs to be followed closely.

Based on all the radiologic information they had at their disposal, they felt that Dylan's mass was probably a congenital hemangioma, the least life-threatening of the three diagnoses.

But their work was not done. After the tests Barnewolt, Estroff and Fishman met with Jennings to review films, discuss their findings and make a plan of action; even though they felt they knew what Dylan's mass was, they still wanted to plan for any eventuality. "There was still the chance that it could be an AVM," says Fishman, "so we needed to plan on being in the operating room during delivery in case it began to bleed."

While AFCC staff planned their course of action, Dawn and Jeff returned to Florida to give Dylan time to develop so he would have a better chance of surviving when he was delivered. Dawn also continued taking medication to boost the efficiency of Dylan's strained heart so it wouldn't be overwhelmed by the task of providing blood to the mass.

The Methvens returned to Boston in July for a checkup and to see if Dylan was ready to be delivered. Estroff and Barnewolt did another ultrasound and MRI to see how Dylan and the mass had progressed, and cardiologist Wayne Tworetzky, MD, did an echocardiogram to assess Dylan's heart function. "The echo lets us see the blood flow through the heart and helps us see if there are any abnormalities," says Tworetzky. "We can also see if there is any accumulation of fluid around the heart that can be a sign of trouble." Results showed that, despite the pressure caused by the mass, Dylan's heart was holding up.

After all the information from these tests was gathered, Fishman, Jennings and other members of the AFCC team met with Dawn and Jeff once again and explained the scenarios they were most likely to encounter in the operating room during the delivery.

"I'm a straight shooter," Fishman told them. "I'm going to tell you the information we know, but also that what we think we know and what we see in the delivery room could be very different."

At the end of the consultation, Fishman asked Dawn how she was holding up. She told him that she and Jeff were encouraged that Dylan was continuing to grow, and that the more they learned about his diagnosis and what his odds were, the more hopeful they became. "When we found out about the mass, Dylan was 2.7 pounds," said Dawn. "Now he's 6.7. He's growing, he's fighting and we have to fight for him."

On July 29 Dylan James Methven was delivered by Caesarean section. Fishman was in the O.R. to evaluate Dylan's mass, and found that the skin covering it was intact and seemed sturdy. Dylan's heart rate and oxygen levels looked good and were improving, so Fishman decided that no intervention was immediately necessary.

With this news, the Methvens could finally stop holding their breath. Dylan was going to be okay.

continued on next page

Congenital diaphragmatic hernia

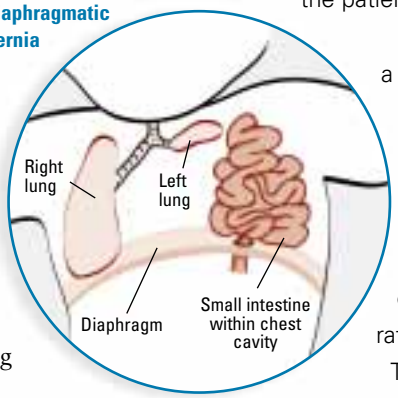

Illustration: Patrick Bibbins

Closing the loop

Multi-specialty care leads to world-class outcomes for CDH babies

At age 3 James Hanron is learning to eat on his own for the first time.

Imagine a pair of hands squeezing your lungs. At first the grip is light, but gets progressively tighter until you can no longer breathe. This is what happens to children diagnosed with congenital diaphragmatic hernia (CDH), a condition where a hole in the diaphragm—the breathing muscle separating the chest and abdomen—allows the body's organs to move into the chest and slow normal lung growth.

CDH occurs once in about every 2,500 births and causes a host of problems in addition to impairing lung development, including heart conditions, developmental delays, feeding difficulties and even death. Treatment of the condition sounds relatively simple—surgically pull the organs back into their normal positions and close the hole in the diaphragm—but when the patient is a fetus, nothing is as simple as it seems.

In the CDH Clinic at Children's Hospital Boston, a 20-member team of specialists from a variety of medical and surgical fields works together to treat approximately 30 CDH babies each year, and follows more than 175. Their decades of experience have paid off as the Children's program has the highest rates of successful CDH outcomes in the world, with an overall survival rate exceeding 90 percent.

These skills were brought to bear on James Hanron before he even came into the world. When his parents Sarah and David Hanron found out during a prenatal exam that James had CDH, they met with Jay Wilson, MD, clinical director of the CDH Clinic, who explained that James might need to be placed on extracorporeal membrane oxygenation (ECMO), a machine that would work as his lungs, providing oxygen to his blood and body.

When James was delivered it immediately became apparent that he wasn't breathing well, so he was monitored in the intensive care unit for four days before being hooked up to ECMO. Wilson and his surgical team took the opportunity to repair James' herniated intestine and pull his liver back down to allow his tiny lungs room to grow. James spent three months in the ICU before finally going home.

Despite a reherniation of his large bowel in early 2002 that required another operation, James continues to grow and breathes without the help of an oxygen tank. And after three years of getting his nutrition through a feeding tube, he is learning how to eat on his own.

Shortly thereafter, the Methvens returned to Florida with the baby they had been waiting nearly four years for in tow. "We consider Dylan our little miracle," says Dawn. "I feel like everyone at Children's watched over him to make him the little angel we have today."

Photo: Julie Fletcher/Orlando Sentinel

While Dylan did not require the emergent surgical intervention that the AFCC is known for worldwide, several patients have undergone invasive and innovative procedures at the center. One example is a fetus diagnosed with a defect in which one of his heart valves was too narrow to pump blood. AFCC specialists, in conjunction with physicians from Brigham and Women's Hospital, were able to correct the problem by inserting a needle into the mother's abdomen and dilating a small balloon to open the narrowed valve. Today the baby boy has a healthy, functioning heart.

Even though her son didn't need these extreme life-saving measures, Dawn Methven is now a firm believer in the miracle of fetal diagnostic medicine. "The diagnostic piece allows doctors to make educated decisions before birth," says Dawn. "As a parent that's all I could ask for, and I feel we had the best diagnostic care available. Knowing what the possibilities were and what options we had made all the difference in the world."

—*Susan Craig*

The Advanced Fetal Care Center (AFCC) at Children's Hospital Boston serves families facing complex birth defects and other critical challenges to the health of their unborn and newborn infants. For more information about AFCC's services or to schedule an appointment or consultation, call 1-866-FETAL-CARE or visit www.childrenshospital.org.

For more information on how you can support the AFCC, contact Julie Considine in the Children's Hospital Trust at (617) 355-6193 or julie.considine@chtrust.org.