Treatment of Iliac Crest Apophysitis in the Young Athlete With Bone Stimulation: Report of 2 Cases

Courtney Grace Kivel, BS,‡ Charles Allou d'Hemecourt, BS,* and Lyle Joseph Micheli, MD*†*

Key Words: treatment, iliac crest, apophysitis, young athlete, bone stimulation, iliac crest apophysitis, adjunct therapy, electrical stimulation, ultrasound

(*Clin J Sport Med* 2011;21:144–147)

INTRODUCTION

One class of sports injuries unique to the child athlete are injuries to the growth cartilage. Growth cartilage in the child is present at the physeal plates of long bones, articular cartilage, and the apophyseal insertions of major muscle tendon units.[1] Each of these 3 sites may be injured by acute trauma, repetitive trauma, or combinations of the two, as when an apophysis weakened by repetitive stress is subjected to a single overload and is avulsed from its bony insertion.

Repetitive overuse injuries to the apophysis resulting in pain, swelling, or partial avulsion to the apophyses have been labeled as apophysitises, reflecting earlier observers' beliefs that this involved an inflammatory process. More recently, it has been suggested that these injuries are actually subclinical fractures at these sites, similar to stress fractures seen in the long bones.[1–3]

There are 7 apophyses located about the hip and pelvis (Figure 1), and all have been reported as sites of both acute traumatic avulsion and apophysitis. Iliac crest apophysitis is relatively rare but is encountered more frequently as an overuse injury than the other peripelvic apophyses.

A study of apophysitises presenting to the Sports Medicine Division of Boston Children's Hospital between 1980 and 1990 reported 32 cases of iliac crest apophysitis out of a total of 445 apophyseal injury cases treated during that time, for a total of 7%.[1] Although relatively uncommon, iliac crest apophysitis can be difficult to resolve. Treatments reported include physical therapy, activity modification, anti-inflammatories, and compressive garments.[1,3]

Risser[4] noted that the iliac apophysis appears initially laterally and anteriorly and then ossifies posteriorly progressing on to total bony union. This apophysis is one of the last to close in the body, with the average chronologic age of completion being 16 years in boys and 14 years in girls, but can occur as late as 20 years in boys and 18 years in girls.[4]

The use of electrical stimulation for the treatment of delayed union of long bone fractures dates back to the 1800s but has only recently been used to treat sports injuries.[5]

For some years, the senior author (L.J.M.) has been using electrical stimulation to treat not only delayed unions of long bone fractures, but also select cases of osteochondritis dissecans, spondylolysis stress fracture of the low back, and apophysitis.[6] Over the past 2 years, he has treated 6 cases of iliac crest apophysitis with adjunct bony stimulation and has had a favorable clinical impression of these outcomes and the ability of these treatments to speed the rate of healing. The clinical and radiographic details of 2 of these cases will be presented below.

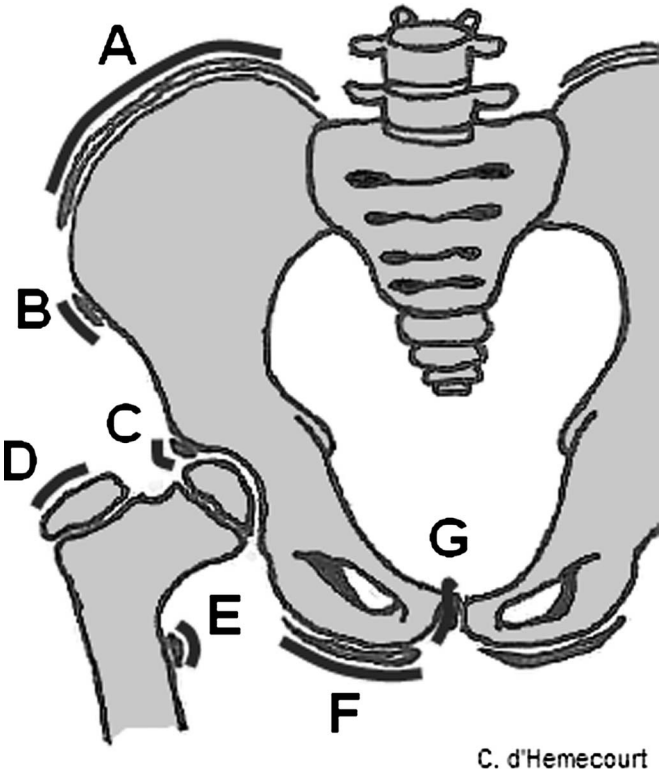

FIGURE 1. Apophyses located about the hip and pelvis. Iliac crest (A), anterior superior iliac spine, (B), anterior inferior iliac spine, (C), greater trochanter (D), lesser trochanter (E), ischial tuberosity (F), and pubic symphysis (G). Illustrated by Charles A. d'Hemecourt.

Submitted for publication July 5, 2010; accepted January 5, 2011.
From the *Division of Sports Medicine, Children's Hospital, Boston, Massachusetts; †Harvard Medical School, Boston, Massachusetts; and ‡Columbia University, New York, New York.
The authors report no conflicts of interest.
Corresponding Author: Lyle J. Micheli, MD, Division of Sports Medicine, Children's Hospital Boston, 319 Longwood Ave, Boston, MA 02115 (e-mail: lyle.micheli@aol.com).

CASE 1

An 11-year-old female Irish step dancer presented with a 2-month history of left hip pain that was exacerbated by activity. On physical examination, there was palpable tenderness along the left anterior iliac crest apophysis.

Anteroposterior (AP) radiographs of the pelvis revealed changes consistent with left sided iliac crest apophysitis (Figure 2A), and the patient was advised to continue dance as tolerated, treat symptoms with ice and anti-inflammatories, and use an Exogen (Smith & Nephew, Inc, Memphis, Tennessee) bone stimulator system for 20 minutes, twice daily.

At 2-month follow-up, improvement was noted in symptoms, on physical examination, and on repeat AP pelvis radiographs (Figure 2B).

At 4-month follow-up, the patient reported that she had no pain, despite full dance activity. An AP pelvis radiograph demonstrated dramatic healing of the iliac apophysis as compared with the initial x-ray (Figure 2C).

On return to clinic 2 months later, AP pelvis radiographs showed further healing (Figure 2D). The patient had continued to use her bone stimulator and was able to do her Irish step dance without pain or limitations.

CASE 2

A 17-year-old female pole vaulter presented with tenderness over the left iliac crest. Anteroposterior radiographs of the pelvis confirmed left iliac crest apophysitis with widening of the apophysis (Figure 3A).

The patient was referred to physical therapy for pelvic strengthening, instructed to continue to wear compression shorts while training, and to avoid painful maneuvers. The patient followed up at 3 and 5 months without improvement. Seven months after initial presentation, the patient returned to clinic. Repeat radiographs showed apophyseal displacement with little improvement (Figure 3B). Electrical bone stimulation was then added to the treatment.

After 7 weeks, at a follow-up, there was no pain on examination. Nine-month radiographs can be seen in Figure 3C. An additional 6 weeks of bone stimulation was recommended.

After 6 weeks, the patient returned to clinic with no pain over her left iliac crest. Radiographs at 10 months displayed further healing (Figure 2D).

DISCUSSION

In both the 11-year-old dancer and the 18-year-old pole vaulter, conservative treatment modalities coupled with daily electrical stimulation resulted in progressive healing of the iliac crest apophysis, as demonstrated by comparison of initial and final radiographs and complete resolution of symptoms on clinical examination. Time between initiation of the bone stimulator and most recent follow-up was 17 and 14 weeks, respectively.

Although the mechanism of injury in iliac apophysitis is uncertain, it is thought that the condition may arise as a result of subclinical stress fractures to the apophysis.[3] This is also

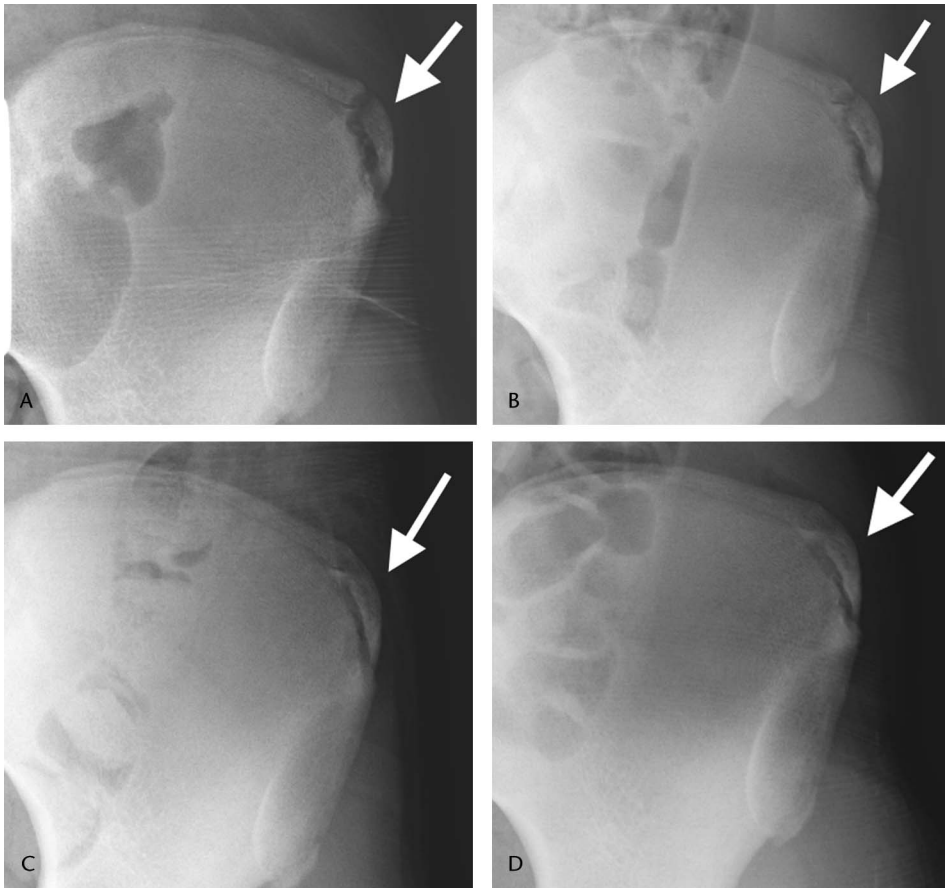

FIGURE 2. Case 1. Anteroposterior pelvis radiographs at initial visit (A) and at 2-month (B), 4-month (C), and 6-month follow-up (D).

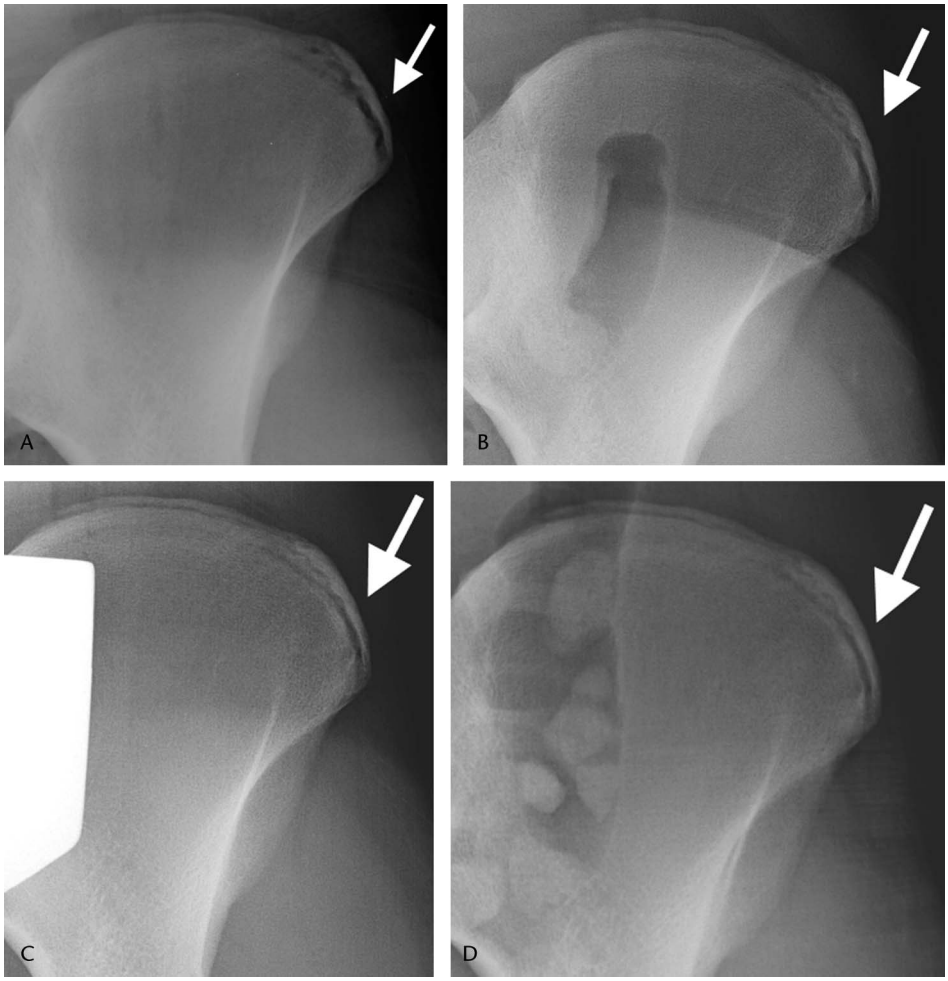

FIGURE 3. Anteroposterior pelvis radiographs at baseline (A) and at 7 months (B), 9 months (C), and 10 months (D).

described as multiple tiny avulsion fractures, which arise from repetitive microtrauma to the apophyseal area.[1] This injury is most often seen in distance running, dance, and other sports that lend themselves to training repetition and impact.[1]

In animal studies, electrical stimulation has been shown to induce enhanced callus formation[7] and to impact cellular pathways, such as growth factor synthesis,[8] proteoglycan and collagen regulation,[9] and cytokine production.[10]

There have been a number of clinical studies that support the benefit of adjunctive fracture healing techniques with electrical fields or ultrasound. These studies each used a randomized, double-blind, placebo-controlled methodology, and all yielded statistically significant results. In 1990, Sharrard[11] demonstrated the benefits of pulsed electromagnetic field stimulation on fracture healing. The study found that the use of an electric bone stimulator was statistically significant for a positive effect on delayed union tibial fractures, in which 45% (9 of 25) of the active group of patients progressed to union as opposed to 14% (2 of 22) of the placebo group. In 2005, Gebauer et al[12] reported a self-paired control study in which 67 nonunion cases were treated with low-intensity pulsed ultrasound applied for 20 minutes daily. After an average of 167 days, 85% (57 of 67) of the patients were clinically and radiographically healed, a rate comparable with outcomes after surgical intervention. In a prospective randomized study, Heckman et al[13] demonstrated that low-intensity pulsed ultrasound-treated tibial fractures healed 38% faster than nonultrasound-treated fractures when applied for 20 minutes daily.

Our positive outcomes with adjuvant bone stimulation therapy for the treatment of iliac crest apophysitis are encouraging. To our knowledge, although there is evidence to support the use of bone stimulators in fracture healing, there are no prospective clinical studies to date that describe the use of electrical or ultrasound bone stimulators for iliac crest apophysitis.

Appropriately designed and validated studies are needed to further support these observations. Currently, several questions remain unanswered. Trials similar to those used to test the efficacy of the bone stimulator in fracture healing can be used to address these questions, provided that the investigator is able to achieve a large enough patient population to render the study statistically sound. This research will impact the future directives and clinical indications for bone stimulation. There is potential for improved outcomes in the treatment of apophysitis and the opportunity for further investigation into alternate indications for bone stimulation in the treatment of other conditions requiring bone healing and new bone formation.

REFERENCES

1. Micheli LJ, Fehlandt AF. Overuse injuries to the tendons and apophyses in children and adolescents. *Clin Sports Med*. 1992;11:713–726.
2. Ogden JA, Ganey TM, Hill JD, et al. Sever's injury: a stress fracture of the immature calcaneal metaphysis. *J Pediatr Orthop*. 2004;4:488–492.
3 Clancy WG, Foltz AS. Iliac apophysitis and stress fractures in adolescent runners. *Am J Sports Med*. 1976;4:214–218.
4. Risser JC. The iliac apophysis: an invaluable sign in the management of scoliosis. *Clinical Orthop*. 1958;11:111–113.
5. Lente RW. Cases of un-united fracture treated by electricity. *N Y State J Med*. 1850;5:317–319.
6. Fellender-Tsai L, Micheli LJ. Treatment of spondylolysis with external electrical stimulation and bracing in adolescent athletes: a report of two cases. *Clin J Sport Med*. 1998;8:232–234.
7. Furkado E, Yasuda I. On the piezoelectric effect of bone. *J Phys Soc Japan*. 1957;12:1158–1169.
8. Aaron RK, Boyan BD, Ciombor DM, et al. Stimulation of growth factor synthesis by electric and electromagnetic fields. *Clin Orthop Relat Res*. 2004;419:30–37.
9. Ciombor DM, Aaron RK. The role of electrical stimulation in bone repair. *Foot Ankle Clin*. 2005;10:579–593.
10. Spadaro JA. Mechanical and electrical interactions in bone remodeling. *Bioelectromagnetics*. 1997;18:193–202.
11. Sharrard WJW. A double blind trial of pulsed electromagnetic field for delayed union of tibial fractures. *J Bone Joint Surg*. 1990;72B: 347–355.
12. Gebauer D, Mayr E, Orthner E, et al. Low-intensity pulsed ultrasound: effects on non unions. *Ultrasound Med Biol*. 2005;31: 1391–1402.
13. Heckman JD, Ryaby JP, McCabe J, et al. Acceleration of tibial fracture-healing by non-invasive, low-intensity pulsed ultrasound. *J Bone Joint Surg Am*. 1994;76:26–34.