

# Serial Transverse Enteroplasty for Short Bowel Syndrome: A Case Report

By Heung Bae Kim, Patricia W. Lee, Jennifer Garza, Christopher Duggan, Dario Fauza, and Tom Jaksic  
Boston, Massachusetts

The patient is a 2-year-old boy born with gastroschisis and midgut volvulus that left him dependent on total parenteral nutrition (TPN). At 11 months of age, a Bianchi procedure was performed increasing the total length of bowel from 72 cm to 130 cm. Although he appeared to have sufficient bowel length, he continued to have malabsorption and could only tolerate 10% of his caloric requirement enterally. A barium study found significant dilatation of the lengthened small bowel. At 23 months, we performed a novel bowel lengthening procedure that we have reported previously in an animal model. The serial transverse enteroplasty (STEP) operation increased the 83 cm of dilated and previously lengthened bowel to 147 cm, making the total small bowel length 200 cm. The patient tolerated the procedure well and began

to have semisolid bowel movements. Small intestinal absorptive capacity measured by D-xylose absorption showed a substantial increase from 5 to 12 mg/dL (normal range, >20), implying improved but not completely normal small bowel function. This case shows that the STEP procedure increases intestinal length, can be used after a prior Bianchi, and may result in improved intestinal absorptive capacity. The STEP procedure should be considered a surgical option for children with short bowel syndrome.

*J Pediatr Surg* 38:881-885. © 2003 Elsevier Inc. All rights reserved.

INDEX WORDS: Short bowel syndrome, bowel lengthening, bowel tapering, serial transverse enteroplasty, Bianchi

**T**HE SURGICAL APPROACH to short bowel syndrome includes a variety of procedures designed to delay intestinal transit, taper dilated intestine, lengthen the bowel, or replace the lost bowel with an intestinal transplant.<sup>1</sup> Intestinal adaptation after massive small bowel loss frequently results in dilatation of the residual bowel making the tapering/lengthening procedures an attractive first step. Current options include the procedures described by Bianchi<sup>2</sup> and Kimura and Soper.<sup>3</sup> However, the bowel after these types of procedures has been known to redilate resulting in recurrent problems with stasis and bacterial overgrowth, and thus, sequential intestinal lengthening procedures may be useful.<sup>4</sup> Recently, we have described a novel intestinal lengthening procedure in an animal model that may be used after a prior Bianchi procedure or primarily.<sup>5</sup> Here, we report the first clinical application of this procedure in a child who underwent a Bianchi procedure but in whom recurrent bowel dilatation developed, and the patient remained TPN dependent.

## CASE REPORT

The patient is a 2-year-old boy born at 37 weeks' gestation with a prenatally diagnosed gastroschisis. At birth, the infant was noted to have necrotic bowel emanating from a small abdominal wall defect. The infant was transferred emergently to this institution for surgical intervention. At operation, the child was found to have 55 cm of viable but very dilated jejunum distal to the

ligament of Treitz and a viable colon from the splenic flexure distally. The remainder of the bowel was necrotic. An end jejunostomy and Hartmann's procedure were performed with resection of the necrotic bowel. The child was started on TPN. Intestinal continuity was restored at 3 months of age. He continued to have feeding intolerance because of poor motility and bacterial overgrowth in a dilated jejunum. He underwent a Bianchi intestinal lengthening procedure at 11 months of age, during which his small bowel length was increased from 72 cm to 130 cm, as measured from the pylorus to the colon. Unfortunately, despite what appeared to be adequate intestinal length after this procedure, he remained TPN dependent, and a barium study showed that he had recurrent dilatation of his already lengthened jejunum (Fig 1A).

After extensive counseling regarding surgical options for the management of the recurrent dilatation, the patient and family consented to undergo a novel intestinal

*From the Departments of Pediatric Surgery and Gastroenterology and Nutrition, Children's Hospital Boston, MA, and Harvard Medical School, Boston, MA.*

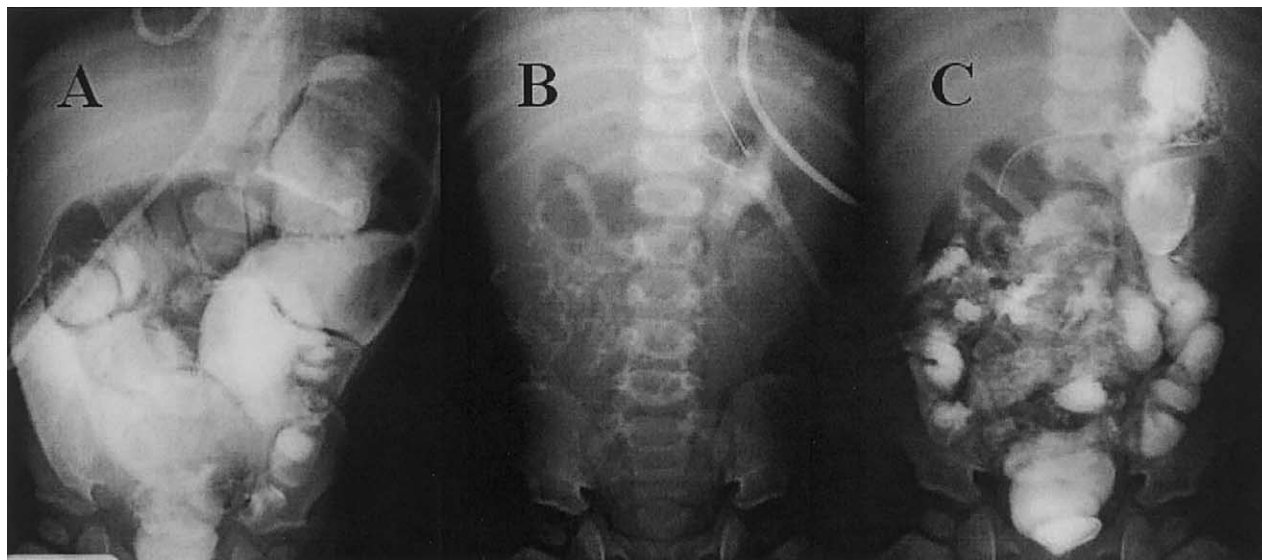
*Presented at the 54th Annual Meeting of the Section on Surgery of the American Academy of Pediatrics, Boston, Massachusetts, October 18-20, 2002.*

*Address reprint requests to Tom Jaksic, MD, PhD, Children's Hospital, 300 Longwood Ave, Fegan 3, Boston, MA 02115.*

© 2003 Elsevier Inc. All rights reserved.

0022-3468/03/3806-0012\$30.00/0

doi:10.1016/S0022-3468(03)00115-5



**Fig 1.** (A) Massively dilated bowel almost one year after Bianchi procedure. (B) Plain abdominal x-ray appearance after STEP with multiple linear staple lines. (C) Contrast study after STEP shows significant improvement in bowel dilatation and no obstruction with passage of barium to rectum in 50 minutes.

lengthening and tapering procedure, the serial transverse enteroplasty (STEP). Informed consent for the operation was obtained with the oversight of the Clinical Investigation Committee at the Children's Hospital, Boston.

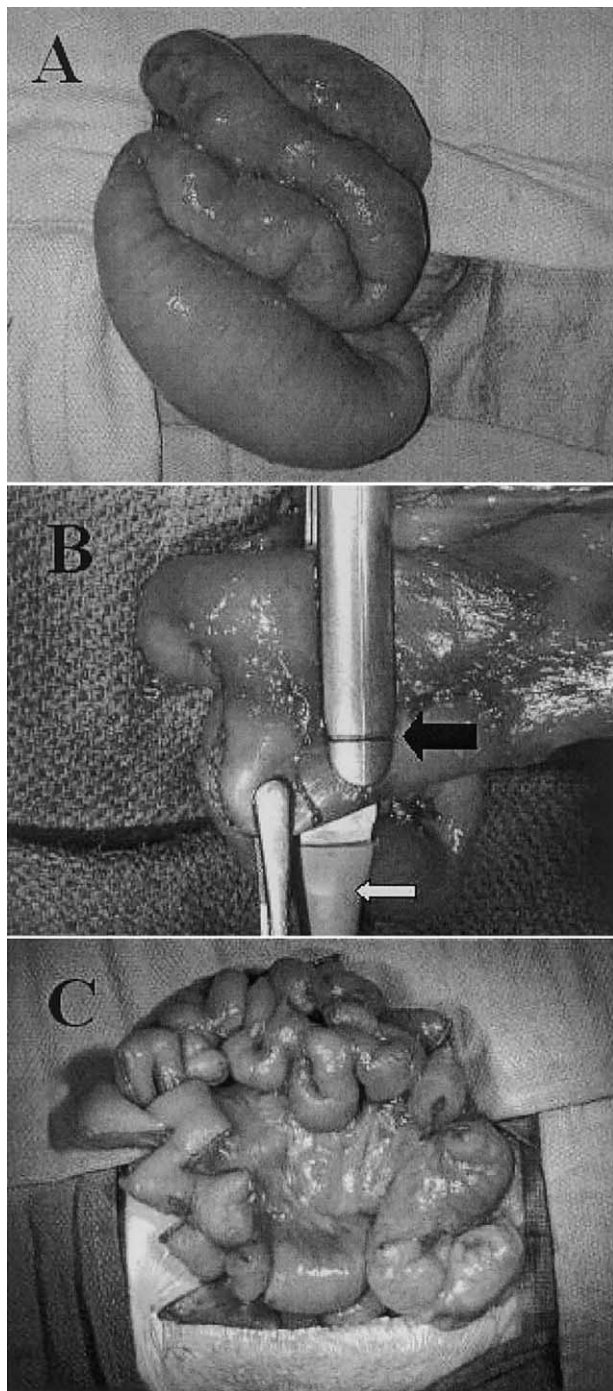
At 23 months of age, the patient underwent reexploration and was found to have significantly dilated jejunum, primarily in the area of the Bianchi procedure (Fig 2A). He had a total length of 135 cm from the pylorus to the colon. A total of 82 cm of the distal jejunum was dilated to a maximum diameter of 6 cm. The serial transverse enteroplasty procedure was performed on this dilated segment of bowel as described previously in the animal model.<sup>5</sup> A line was drawn along the antimesenteric border of the dilated intestine to help keep the correct orientation. Starting at the most proximal part of the dilated bowel, a small mesenteric defect was created and an 18F red rubber catheter was passed through the defect. This was used as a guide to pass the larger side of an endoscopic GIA stapler through the mesentery. We have tried passing both the larger and the smaller side through the mesentery. Although the larger side requires a larger mesenteric defect, accurate application of the stapler leaving the appropriate gap at the end is much easier when the smaller side is visible, because the mark for the end of the staple line is visible (Fig 2B). The bowel was flattened keeping the antimesenteric line directly in the middle while the stapler was applied leaving approximately 2 cm of bowel uncut at the end. The next firing of the stapler was approximately 2 cm distal to this, and the stapler was brought in from the opposite side. This was repeated 26 times along the length of dilated bowel,

essentially creating a channel of bowel with a 2-cm lumen. All stapler applications were kept perpendicular to the long axis of the bowel, thus preserving good blood supply to the intestines. Stapling across the previous Bianchi staple lines was not difficult. The dilated segment was lengthened from 83 cm to 147 cm (Fig 2C). The mesenteric defects were small and were not closed. Seprafilm (Genzyme, Cambridge, MA) anti-adhesion barrier was used before closure.

The postoperative course was uncomplicated, and feedings were restarted within 2 weeks. A plain film showed multiple staples and no dilated bowel (Fig 1B), and results of a barium study showed no leak or obstruction and a good tapering effect (Fig 1C). He began having semisolid bowel movements for the first time and has slowly advanced feedings. To measure small intestinal absorptive capacity, the blood concentration of D-xylose was measured one hour after a 0.5 g/kg oral dose both before and after the STEP procedure.<sup>6</sup> The results showed a substantial increase from 5 to 12 g/dL (normal range, >20), suggesting that the STEP procedure may result in improved small bowel absorptive function. Now, 6 months after the STEP procedure, he is taking about 50% of his calories enterally and is weaning from TPN. There is no evidence of TPN-associated cholestasis.

## DISCUSSION

Intestinal lengthening procedures have been shown to improve intestinal function in children with short bowel



**Fig 2.** (A) Appearance of dilated bowel at time of STEP. (B) Stapler being applied with red rubber catheter (white arrow) guiding larger end of stapler through mesenteric defect and notch (black arrow) on stapler showing where staple line will end. (C) Bowel after STEP procedure is complete.

syndrome.<sup>7</sup> Like the Bianchi procedure, the STEP takes advantage of the natural tendency of the bowel in these patients to dilate. With the STEP procedure, the more dilated the bowel, the more lengthening can be accomplished. An additional benefit of the STEP is that it can be performed after a prior Bianchi procedure if dilatation recurs. This allows sequential bowel lengthening procedures that can more than double the length of the original bowel. This first clinical application of the STEP was performed in a patient after a prior Bianchi, because this child had no other surgical options except for a sequential Kimura procedure,<sup>4</sup> which is likely much more technically challenging than the STEP.

Several issues merit discussion in this case. First, although this child had approximately 200 cm of bowel at the completion of the 2 sequential bowel lengthening procedures, this was still created from only 55 cm of proximal jejunum that was involved in a gastroschisis. Therefore, it is not surprising that he continues to require TPN while this bowel adapts. Second, although this first clinical case was performed in the presence of significantly dilated bowel, the STEP can be performed in bowel that is much less distended as well as irregularly dilated, because each staple line can be tailored to determine the channel size. We chose a channel size of 2 cm in this case based on our previous experience in an animal model<sup>5</sup> as well as the size match with the proximal nondilated bowel. If a smaller channel size is selected, more lengthening can be achieved in bowel of smaller initial diameter. Lastly, as in the animal model, the STEP can be performed as a primary bowel-lengthening procedure. However, maximal bowel lengthening can probably be achieved when it is performed sequentially after a Bianchi procedure, as in this case. We recently have performed the STEP procedure successfully in a child who was not a candidate for a Bianchi based on inadequate and irregular dilatation of the bowel (manuscript in preparation).

This case shows the safety and feasibility of the STEP procedure after a Bianchi procedure. This patient had improved intestinal absorptive capacity after the STEP procedure and has clinically improved with significant progress toward TPN independence. However, additional studies will be required to determine the full physiologic impact of this operation on children who suffer from short bowel syndrome.

## REFERENCES

1. Thompson JS, Langnas AN, Pinch LW, et al: Surgical approach to short-bowel syndrome. Experience in a population of 160 patients. *Ann Surg* 222:600-605; discussion 605-607, 1995
2. Bianchi A: Intestinal loop lengthening—A technique for increasing small intestinal length. *J Pediatr Surg* 15:145-151, 1980

3. Kimura K, Soper RT: A new bowel elongation technique for the short-bowel syndrome using the isolated bowel segment Iowa models. *J Pediatr Surg* 28:792-794, 1993
4. Georgeson K, Halpin D, Figueroa R, et al: Sequential intestinal lengthening procedures for refractory short bowel syndrome. *J Pediatr Surg* 29:316-320; discussion 320-311, 1994
5. Kim HB, Fauza D, Garza J, et al: Serial transverse enteroplasty

(STEP): A novel bowel lengthening procedure. *J Pediatr Surg* 38:425-429, 2003

6. Craig RM, Ehrenpreis ED: D-xylose testing. *J Clin Gastroenterol* 29:143-150, 1999
7. Figueroa-Colon R, Harris PR, Birdsong E, et al: Impact of intestinal lengthening on the nutritional outcome for children with short bowel syndrome. *J Pediatr Surg* 31:912-916, 1996

## Discussion

*K. Georgeson (Birmingham, AL):* I, and I think many others, are awed by the simplicity of this operation, and I think it is a real “step” forward. One of the questions that I have is, obviously you are dealing with a patient that most of us would feel should be absorbing better with that kind of bowel length. Could you speculate why you think this patient does not absorb better with 200 cm of bowel?

The other issue has to do with motility, and that is, gastroschisis patients have notoriously bad motility. I wonder if that doesn't have some impact, and I wonder if, in 2 years, you may see some of that same dilation that you showed after the Bianchi technique.

*H. Kim (response):* Thank you for those kind comments. We also were surprised that he did not absorb better with 200 cm of bowel. We suspect it may have something to do with the fact that he did have a gastroschisis and, in our experience, these patients have poor absorption. But one of his problems preoperatively was the bowel dilation, which was fixed by this procedure.

*B. Warner (Cincinnati, OH):* Congratulations, that was a beautiful presentation. I congratulate your group on a real ingenious way to both taper and lengthen the intestine. As you know, the other standard way to do those 2 things is the Bianchi procedure. Other than being a little bit technically easier, can you tell us when you would use this procedure over the Bianchi procedure, primarily?

*H. Kim (response):* This child had already had a Bianchi procedure, and the reason we did this procedure on him now was that he had redilated his bowel and was having problems with bacterial overgrowth and stasis from that. We did show that it is safe to perform this procedure after a Bianchi because the orientation of the blood supply has not changed with the Bianchi. We have done this procedure on one child primarily. The reason we did it on that child is that she was not progressing with her feedings, she had 19 cm of small bowel and liver disease was developing. When we operated on her, our plan was to do a Bianchi if she had enough dilated bowel, but she did not. So we proceeded with this procedure in the hopes that we could get her on signif-

icant enteral nutrition and stop the progression of her liver disease.

*D. Lund (Madison, WI):* This is a very nice paper, and a very nice technique. As an adjunct to Dr Warner's question, the first time a patient needs bowel lengthening, would you do this, or would you do a Bianchi? My other question is that when Bianchi wrote his first paper he suggested that the bowel had to be 5 cm in diameter to do the procedure. With small anvil staplers you can actually get away with doing a Bianchi on bowel with a much smaller diameter. What is your minimum requirement for the diameter of the bowel to do this STEP procedure?

*H. Kim (response):* I think our plan when we go in to operate on these patients is to try to do a Bianchi if the bowel is dilated enough because you leave open the option to do sequential bowel lengthening in that case. You could do the Bianchi first, followed by the STEP. The converse is not true, you probably cannot do a Bianchi after the STEP, for obvious reasons. So, as in this child, he failed the Bianchi and redilated his bowel so we went ahead with the STEP procedure. In the other child I discussed previously, where we did a primary STEP procedure, we did a primary STEP procedure because of insufficient bowel dilation with a bowel diameter anywhere from 2.5 to 4 cm. We felt this diameter was insufficient to do a Bianchi, and therefore we went ahead with the STEP primarily.

*B. Warner (Cincinnati, OH):* I have just a quick follow-up comment on that. In Dr Bianchi's own series, you know, the long-term survival rate of his patients is about 40% beyond about 5 years postlengthening. And so I would encourage you to follow these patients long term to see whether there are really any differences in our ability. I suspect that probably these patients reach a point of adaptation plateau. They can be lengthened, and their nutrient tolerance can be increased somewhat but it's that degree with which it can increase that is significant. I think a comparison between this operation and the standard Bianchi will be important. It seems that what is primarily going on here in the STEP procedure is the fact that the bowel is so big around, the majority of what you are doing is tapering the bowel rather than

really increasing the nutrient contact time with the mucosa.

*H. Kim (response):* I would completely agree with all those comments. I want to stress that we don't think that this is a replacement for the Bianchi procedure; in fact, I think it is most likely a good adjunct to it.

*M. Brandt (Houston, TX):* Just to sort of follow up on that, all of these procedures actually decrease mucosal absorptive surface if you look just in square centimeters. It has always struck me that the purpose of the Bianchi is really to effect motility. And so I am a little confused by having bowel that is too small to do a lengthening and tapering procedure. I wonder, what is the smallest bowel

you would consider doing this with, and what are you trying to achieve?

*H. Kim (response):* In terms of the technical aspects of the procedure, I think the child in this case report had a 2-cm channel. The child I alluded to earlier in the discussion was less dilated. We have done it actually down to a channel of 1 cm. I think the effect is a result of both tapering and lengthening allowing better contact with enteral nutrition and more contact time for absorption. But, again, you are right; you do lose a little bit of mucosa when you do any of these procedures. We are looking at this now in the laboratory in a short gut model in a pig to see if there is an effect on absorption.