

Brief Report

SEVERE HYPOTHYROIDISM CAUSED BY TYPE 3 IODOTHYRONINE DEIODINASE IN INFANTILE HEMANGIOMAS

STEPHEN A. HUANG, M.D., HELEN M. TU, PH.D.,
JOHN W. HARNEY, M.S., MARIA VENIHAKI, PH.D.,
ATUL J. BUTTE, M.D., HARRY P.W. KOZAKIEWICH, M.D.,
STEVEN J. FISHMAN, M.D., AND P. REED LARSEN, M.D.

HEMANGIOMAS are the most common tumors of infancy, with a prevalence of 5 to 10 percent among one-year-olds. They are characterized by rapid growth in the first year of life, followed by involution and gradual regression by adolescence.^{1,2} We recently treated a three-month-old infant with massive hepatic hemangiomas and primary hypothyroidism who needed very high doses of thyroid hormone to restore euthyroidism and normal thyrotropin secretion. This finding suggested that the rate of degradation of thyroid hormone was accelerated. We subsequently identified high levels of type 3 iodothyronine deiodinase activity in the hemangioma tissue. This selenoenzyme, normally present in the brain and placenta, catalyzes the conversion of thyroxine to reverse triiodothyronine and the conversion of triiodothyronine to 3,3'-diiodothyronine, both of which are biologically inactive. We then retrospectively analyzed other patients with hemangiomas and identified additional patients with similar histories and other hemangiomas with type 3 iodothyronine deiodinase activity.

CASE REPORT

A full-term baby boy was delivered at home after a normal pregnancy. The parents declined to have him undergo thyroid screening. At six weeks of age, he was brought to medical attention because of abdominal distention. Liver biopsy revealed a hepatic hemangioma. The serum thyrotropin concentration was 156 μ U per milliliter (normal range, 0.3 to 6.2), and the serum free

thyroxine concentration was low. The infant was treated with prednisolone (2 mg per kilogram of body weight per day orally) for the hemangioma and levothyroxine (37.5 μ g per day orally). After 5 days of treatment, his serum thyrotropin concentration was 42 μ U per milliliter, but 16 days later it had increased to 256 μ U per milliliter.

At three months of age, the infant was hospitalized for respiratory distress and increasing abdominal distention. His pulmonary status deteriorated rapidly, leading to intubation and transport to the Vascular Anomalies Center at Children's Hospital in Boston. Physical examination revealed marked abdominal distention and hepatomegaly with palpable nodules; the thyroid gland was not enlarged. The patient had intermittent bradycardia and hypothermia (temperature as low as 34°C). Magnetic resonance imaging confirmed the presence of multiple hepatic hemangiomas (Fig. 1). An echocardiogram showed depressed biventricular function (a left ventricular shortening fraction of 27 percent) with a patent foramen ovale and mild tricuspid and mitral regurgitation. The bone age was normal. The serum sodium concentration was 131 mmol per liter, the serum thyrotropin concentration was 177 μ U per milliliter, the serum thyroxine concentration was 2.5 μ g per deciliter (32 nmol per liter), the serum triiodothyronine concentration was less than 15 ng per deciliter (0.23 nmol per liter), the serum reverse triiodothyronine concentration was 413 ng per deciliter (6.36 nmol per liter), and the serum thyroglobulin concentration was 1014 ng per milliliter (normal range, 6 to 87) (Fig. 2).^{3,4}

The initial diagnosis was primary hypothyroidism, presumably congenital, complicated by noncompliance with treatment or impaired absorption of levothyroxine. Methylprednisolone was substituted for prednisolone, and interferon alfa-2b was added to the treatment regimen. The patient's respiratory compromise was thought to be due to hepatomegaly. Emergency embolization and surgery were considered, but the operative risk was deemed unacceptable given the severity of the hypothyroidism. Intravenous administration of liothyronine was initiated in order to correct the hypothyroidism rapidly, and this treatment reduced the infant's serum thyrotropin concentration to 79 μ U per milliliter over a period of 26 hours (Fig. 2), corrected the hyponatremia, and improved cardiac contractility. A continuous intravenous infusion of liothyronine was begun in doses of 24 to 96 μ g per day, to which was added intravenous, and later nasogastric, levothyroxine in doses of 30 to 50 μ g per day. This treatment ultimately lowered serum thyrotropin concentrations to normal and raised serum triiodothyronine concentrations to normal, but serum thyroxine concentrations remained low (Fig. 2). Serum reverse triiodothyronine concentrations were elevated at the time of presentation, fell with the initiation of the liothyronine infusion, and then rose once again to abnormal levels after the reintroduction of levothyroxine (Fig. 2).

On the fourth day of hospitalization, a vertical midline abdominal fasciotomy was performed with the patient under general anesthesia. Two days later, multiple hemangiomas were embolized by hepatic-artery catheterization. Despite transient improvement, the infant remained dependent on mechanical ventilation. The doses of methylprednisolone and interferon alfa-2b were increased, but tumor growth continued. Staphylococcal bacteremia was diagnosed on day 19 of hospitalization. The infection responded to antibiotic therapy, but the infant's clinical status continued to worsen. Liver transplantation was considered and declined by his parents. At their request, he was transferred to a hospital in his home state on day 34. Oliguric renal failure developed six days later, and he died. An autopsy limited to the collection of hemangioma tissue was permitted by the parents.

The cause of this infant's hypothyroidism was still unclear at the time of his death. The high serum thyroglobulin concentration indicated the stimulation of endogenous thyroid tissue.⁵ In adults, the rate of production of triiodothyronine is approximately 32 μ g per day.⁶ By comparison, in this 6.5-kg infant, a daily intravenous dose of up to 96 μ g of liothyronine plus 30 to 50 μ g of levothyroxine led only to a low-normal serum triiodothyronine concentration and did not increase the serum thyroxine concen-

From the Division of Endocrinology (S.A.H., M.V., A.J.B.), the Departments of Pathology and Pediatrics (H.P.W.K.), and the Department of Surgery and the Vascular Anomalies Center (S.J.E.), Children's Hospital; and the Thyroid Division, Department of Medicine, Brigham and Women's Hospital and Harvard Medical School (H.M.T., J.W.H., P.R.L.) — all in Boston. Address reprint requests to Dr. Larsen at the Thyroid Division, Harvard Medical School, Rm. 560, Harvard Institutes of Medicine, 77 Ave. Louis Pasteur, Boston, MA 02115, or at larsen@rascal.med.harvard.edu.

©2000, Massachusetts Medical Society.

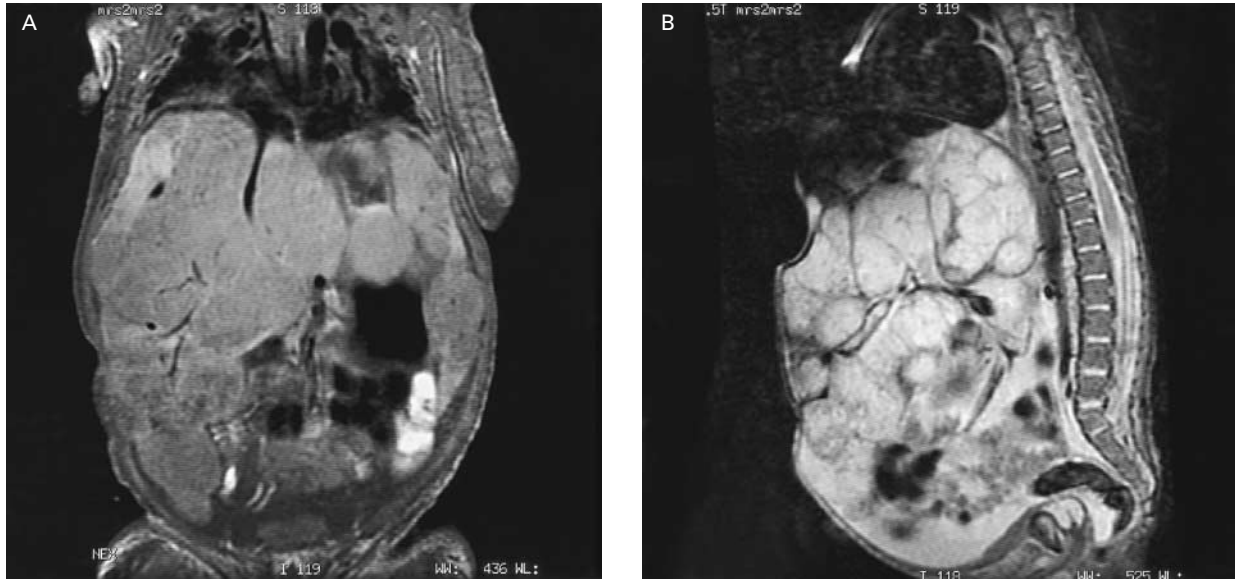


Figure 1. Frontal (Panel A) and Lateral (Panel B) Magnetic Resonance Images of the Abdomen of an Infant with Multiple Hepatic Hemangiomas and Hypothyroidism.

The liver has been diffusely replaced by hemangiomas, which appear as lobular masses within the abdominal cavity that are displacing the intestines inferiorly and raising the diaphragm.

tration (Fig. 2), indicating that the rate of degradation of both hormones was excessively high.

Monodeiodination of the inner ring of thyroxine and triiodothyronine catalyzed by type 3 iodothyronine deiodinase is the chief means of inactivating these hormones, producing reverse triiodothyronine and 3,3'-diiodothyronine, respectively. An increase in the activity of this enzyme could explain the marked increase in serum reverse triiodothyronine concentrations in the infant during treatment with levothyroxine infusion (Fig. 2). Because hypothyroidism was present before interferon alfa-2b was given and worsened in parallel with the growth of the tumors, destruction of thyroid hormone by the hemangiomas or induction of type 3 iodothyronine deiodinase activity by a tumor product was suspected.

METHODS

Tissue Preparation

A review of patients' charts and studies of human tissue were approved by the investigative review board of the hospital. Placental tissue was obtained at term from a woman with no known medical problems. Frozen specimens of hemangioma tissue were recovered from storage at -80°C . Tissue homogenates were suspended in a buffer of 0.1 M phosphate and 1 mM EDTA at pH 6.9 with 10 mM dithiothreitol and 0.25 M sucrose for enzyme analysis or in Trizol reagent (Life Technologies, Rockville, Md.) to isolate RNA.⁷

Type 3 Iodothyronine Deiodinase Assays

Each deiodination reaction included 3 to 150 μg of cellular protein, 200,000 cpm of 3,3',[¹²⁵I]5'-triiodothyronine (New England Nuclear, Boston), 0 or 1 mM 6*N*-propylthiouracil, 10 mM dithiothreitol, and various concentrations of unlabeled triiodothyronine. The reaction was stopped by the addition of ethanol. The labeled substrate and deiodination products were quantified by paper chromatography, and iodothyronines were identified by colorimetry.⁷

Northern Blot Analysis

For the Northern blot analysis, total RNA was isolated with Trizol reagent according to the manufacturer's recommendations. A Northern blot was prepared according to standard methods and probed with a 1.1-kb fragment of human type 3 iodothyronine deiodinase complementary DNA. Relative to the start codon, this fragment included nucleotides -35 to 849.⁷ The blot was stripped and reprobated with rat cyclophilin to adjust for differences in the loading and transfer of the samples.

In Situ Hybridization

For in situ hybridization, 12- μm frozen sections were cut with a cryostat (Leica, Allendale, N.J.) and fixed with 4 percent paraformaldehyde in phosphate-buffered saline. A complementary-RNA probe was prepared that included the same sequences that were used in the Northern blot analysis, and in situ hybridization was performed in which 2×10^7 to 3×10^7 cpm of probe per milliliter was hybridized with the specimens at 65°C for 16 to 20 hours.

Retrospective Review of Patients with Hemangioma

A list of patients with hemangiomas who were seen at Children's Hospital between January 1993 and December 1999 was obtained. Patients were included if they had been given a diagnosis of hemangioma (*International Classification of Diseases, 9th Revision*, codes 228.00 through 228.04 and code 228.09). For each patient, the results of thyroid-function tests were retrieved from computerized laboratory records.

RESULTS

Analysis of Type 3 Iodothyronine Deiodinase Activity in Hemangioma Tissue from the Patient

The patient's hemangioma exhibited type 3 iodothyronine deiodinase activity that was insensitive to incubation with 6*N*-propylthiouracil, with a Michaelis

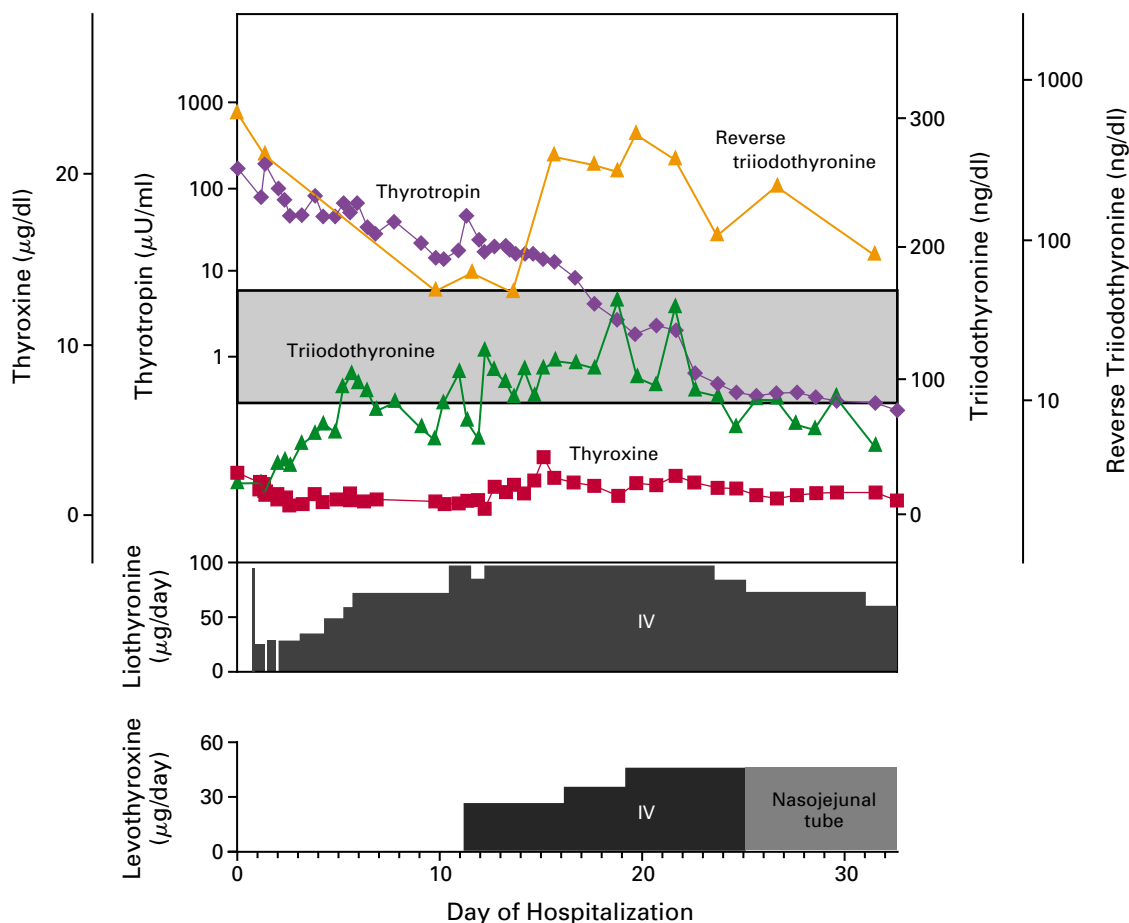


Figure 2. Thyroid Function and Treatment during Hospitalization in an Infant with Multiple Hepatic Hemangiomas.

The shaded region is the normal range for serum thyrotropin concentrations (0.3 to 6.2 μU per milliliter), serum thyroxine concentrations (6.8 to 13.3 μg per deciliter [88 to 171 nmol per liter]), serum triiodothyronine concentrations (86 to 170 ng per deciliter [1.32 to 2.62 nmol per liter]), and serum reverse triiodothyronine concentrations (10 to 50 ng per deciliter [0.15 to 0.77 nmol per liter]). Each value is plotted relative to the normal range. Serum thyrotropin and reverse triiodothyronine concentrations are plotted on a logarithmic (base 10) scale. The infant was treated with intravenous (IV) infusions of both liothyronine and levothyroxine. The route of administration of levothyroxine was changed to nasojejunal on day 25 of hospitalization. To convert values for thyroxine to nanomoles per liter, multiply by 12.87, and to convert values for triiodothyronine or reverse triiodothyronine to nanomoles per liter, multiply by 0.0154.

constant of 2.5 nM for triiodothyronine. The maximal velocity of the activity was 0.78 pmol of triiodothyronine deiodinated per minute per milligram of protein, a value 7.5 times that in placental tissue, which has the highest level of activity under normal circumstances (Fig. 3A).⁷ The type 3 iodothyronine deiodinase complementary-DNA probe hybridized to a single RNA band of approximately 2.2 kb in the hemangioma and placental tissues (data not shown). The ratio of the density of type 3 iodothyronine deiodinase messenger RNA to the density of cyclophilin messenger RNA in the patient's hemangioma tissue was 3.6 times the ratio in placental tissue. In situ hybridization showed that type 3 iodothyronine deio-

dinase messenger RNA originated from hemangioma cells (Fig. 3B and 3C).

Retrospective Review of Patients and Analysis of Type 3 Iodothyronine Deiodinase Activity in Hemangioma Tissue from Other Patients

Among the 1555 patients with hemangiomas whom we identified, serum thyrotropin had been measured in 92 (6 percent), most of whom were scheduled to receive interferon, which can cause thyroid dysfunction.⁸ Nine patients had values that were high for their age.⁹ Excluding the index patient, three patients had serum thyrotropin concentrations that were more than twice the upper limit of the normal range. One was

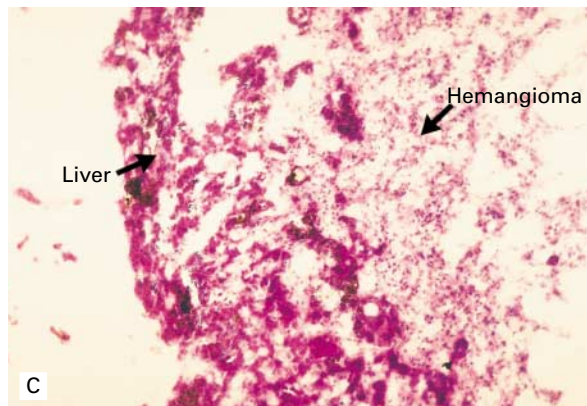
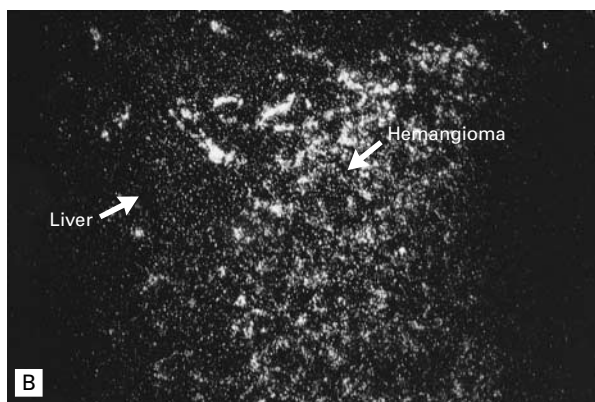
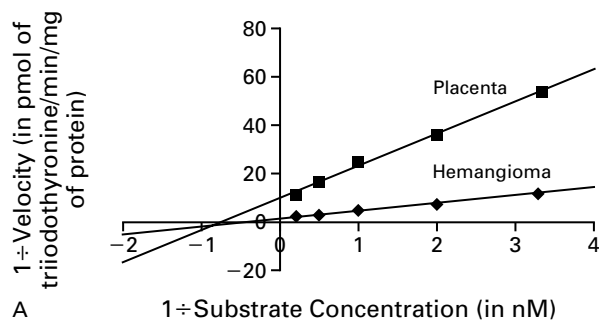


Figure 3. Results of Analysis of Type 3 Iodothyronine Deiodinase Activity and Pathological Studies.

Panel A shows the results of a Lineweaver–Burk analysis of triiodothyronine deiodination by hemangioma tissue from the patient and by placental tissue. Panels B and C show adjacent sections of the patient's hepatic lesion. In Panel B, regions of the in situ hybridization signal indicating the presence of type 3 iodothyronine deiodinase messenger RNA appear bright ($\times 100$). In Panel C, hemangioma is apparent on the right-hand side and primarily uninvolved hepatic tissue is present on the left-hand side (hematoxylin and eosin, $\times 100$). Human type 3 iodothyronine deiodinase complementary RNA binds specifically and preferentially to hemangioma cells.

considered to have congenital hypothyroidism. The other two had had normal results on thyroid screening as newborns and were considered to have acquired hypothyroidism. Like our patient, both had massive hepatic hemangiomas, low serum thyroxine concentrations, and high serum thyrotropin concentrations ($567 \mu\text{U}$ per milliliter at the age of 3 months in one patient and $88 \mu\text{U}$ per milliliter at the age of $2\frac{2}{3}$ years in the other). Hemangioma tissue from these patients was not available for study.

Samples of hemangioma tissue from five other patients were available and were assayed for type 3 iodothyronine deiodinase activity. Three of these specimens had type 3 iodothyronine deiodinase activity, with velocities of 0.017 pmol of triiodothyronine deiodinated per minute per milligram of protein in the case of a hepatic hemangioma specimen and of 0.014 and 0.042 pmol of triiodothyronine deiodinated per minute per milligram of protein in the case of two cutaneous hemangioma specimens, as compared with a velocity of 0.038 pmol of triiodothyronine deiodinated per minute per milligram of protein in the case of placental tissue analyzed at the same time.

DISCUSSION

Our patient had severe biochemical hypothyroidism in association with massive hepatic hemangiomas

and required very high doses of levothyroxine and liothyronine to reduce serum thyrotropin concentrations to normal. Athyrotic infants who are the same age as our patient usually require about $7 \mu\text{g}$ of oral levothyroxine per kilogram daily to restore serum thyrotropin concentrations to normal, whereas our patient required approximately eight to nine times as much, including the daily dose of liothyronine and assuming that 40 percent of the exogenous thyroxine is converted to triiodothyronine.^{6,10,11}

An accelerated rate of inactivation of thyroid hormone by type 3 iodothyronine deiodinase in the hemangioma is the best explanation of this phenomenon, with the enzymatic activity of the tumor, because of its large mass and vascularity, exceeding the synthetic capacity of the infant's thyroid. The presence of a similar, although less severe, abnormality presumably also explains the acquired hypothyroidism in the other two patients we identified. The finding of type 3 iodothyronine deiodinase activity in three of five other hemangioma specimens that we tested indicates that its presence in our patient's hemangioma is not unique. The two other types of iodothyronine deiodinase act primarily on the outer iodothyronine ring, and they have a weak capacity (in the case of type 1) to remove iodine to an inner ring or are unable to do so (in the case of type 2).⁶

The proliferative phase of hemangiomas is characterized by the increased expression of angiogenic factors such as basic fibroblast growth factor.^{1,12} In neonatal glial cells or brown adipocytes from rats, the activity of type 3 iodothyronine deiodinase or the expression of its messenger RNA is increased by incubation with fibroblast growth factors, because these factors activate the extracellular receptor kinase pathway.¹³⁻¹⁶ It seems likely that the high level of expression of type 3 iodothyronine deiodinase in hemangiomas is due to the endocrine or paracrine induction of the enzyme in endothelial cells by basic fibroblast growth factor or other growth factors.

In the first year of life, approximately three to five IQ points are lost for each month in which hypothyroidism remains untreated.¹⁷ This developmentally critical period corresponds to the proliferative phase of hemangiomas and arouses concern that infants with this tumor may be at risk for permanent neurologic damage. Infantile hypothyroidism is often occult, and even severe symptoms could be masked by complications of the hemangioma itself.^{17,18} Impaired hemostasis from hypothyroidism could confound the coagulopathy of hepatic failure or the Kasabach-Merritt syndrome.¹⁹ Cardiac impairment from hypothyroidism could exacerbate the congestive heart failure associated with high-flow hemangiomas.^{20,21} Even the later spastic diplegia and delayed myelination attributed to neurotoxicity induced by interferon in these patients are features of hypothyroidism in infants.²²⁻²⁴

The majority of hemangiomas are small and require no therapy.^{1,2} Given the adaptive capacity of the normal thyroid gland, it is likely that only patients with both high levels of type 3 iodothyronine deiodinase activity and large tumor burdens are at risk for hypothyroidism. Until prospective studies can better quantify this risk, thyroid function should be assessed in children with large hemangiomas before any type of therapy is begun and periodically thereafter, especially if symptoms of hypothyroidism appear or the tumor burden increases rapidly. If hypothyroidism is diagnosed, higher doses of levothyroxine may be needed.

Supported by grants (DK07699, DK07529, and DK44128) from the National Institutes of Health.

We are indebted to the parents of the index patient for allowing medical research to be conducted after his death; to Drs. Joseph Majzoub, David A. Weinstein, Antonio Bianco, and Joyce Bischoff for critically reviewing and discussing the manuscript; to Dr. Diego

Jaramillo for reviewing the radiographic studies; and to Dr. Jerald C. Nelson of Quest Diagnostics (San Juan Capistrano, Calif.) for performing reverse triiodothyronine assays on frozen serum samples.

REFERENCES

1. Drolet BA, Esterly NB, Frieden IJ. Hemangiomas in children. *N Engl J Med* 1999;341:173-81.
2. Fishman SJ, Muliken JB. Hemangiomas and vascular malformations of infancy and childhood. *Pediatr Clin North Am* 1993;40:1177-200.
3. Ket JL, De Vijder JJ, Bikker H, Gons MH, Tegelaers WH. Serum thyroglobulin levels: the physiological decrease in infancy and the absence in athyroidism. *J Clin Endocrinol Metab* 1981;53:1301-3.
4. Chopra IJ, Sack J, Fisher DA. Circulating 3,3',5'-triiodothyronine (reverse T3) in the human newborn. *J Clin Invest* 1975;55:1137-41.
5. Ostergaard GZ, Jacobsen BB. Atrophic, autoimmune thyroiditis in infancy: a case report. *Horm Res* 1989;31:190-2.
6. Larsen PR, Davies TF, Hay ID. The thyroid gland. In: Wilson JD, Foster DW, Kronenberg HM, Larsen PR, eds. *Williams textbook of endocrinology*. 9th ed. Philadelphia: W.B. Saunders, 1998:389-515.
7. Salvatore D, Low SC, Berry M, et al. Type 3 iodothyronine deiodinase: cloning, in vitro expression, and functional analysis of the placental selenoenzyme. *J Clin Invest* 1995;96:2421-30.
8. Koh LK, Greenspan FS, Yeo PP. Interferon-alpha induced thyroid dysfunction: three clinical presentations and a review of the literature. *Thyroid* 1997;7:891-6.
9. Zurakowski D, Di Canzio J, Majzoub JA. Pediatric reference intervals for serum thyroxine, triiodothyronine, thyrotropin, and free thyroxine. *Clin Chem* 1999;45:1087-91.
10. Mandel SJ, Brent GA, Larsen PR. Levothyroxine therapy in patients with thyroid disease. *Ann Intern Med* 1993;119:492-502.
11. Germak JA, Foley TP Jr. Longitudinal assessment of L-thyroxine therapy for congenital hypothyroidism. *J Pediatr* 1990;117:211-9.
12. Takahashi K, Mulliken JB, Kozakewich HP, Rogers RA, Folkman J, Ezekowitz RA. Cellular markers that distinguish the phases of hemangioma during infancy and childhood. *J Clin Invest* 1994;93:2357-64.
13. Hernandez A, St Germain DL, Obregon MJ. Transcriptional activation of type III inner ring deiodinase by growth factors in cultured rat brown adipocytes. *Endocrinology* 1998;139:634-9.
14. Courtin F, Liva P, Gavaret JM, Toru-Delbauffe D, Pierre M. Induction of 5-deiodinase activity in astroglial cells by 12-O-tetradecanoylphorbol 13-acetate and fibroblast growth factors. *J Neurochem* 1991;56:1107-13.
15. Pallud S, Ramage M, Gavaret JM, et al. Regulation of type 3 iodothyronine deiodinase expression in cultured rat astrocytes: role of the Erk cascade. *Endocrinology* 1999;140:2917-23.
16. Hernandez A, Obregon MJ. Presence of growth factors-induced type III iodothyronine 5-deiodinase in cultured rat brown adipocytes. *Endocrinology* 1995;136:4543-50.
17. Fisher DA. Management of congenital hypothyroidism. *J Clin Endocrinol Metab* 1991;72:523-9.
18. LaFranchi S. Congenital hypothyroidism: etiologies, diagnosis, and management. *Thyroid* 1999;9:735-40.
19. Myrup B, Bregengard C, Faber J. Primary haemostasis in thyroid disease. *J Intern Med* 1995;238:59-63.
20. Balducci G, Acquafredda A, Amendola F, Natuzzi M, Laforgia N, Cavallo L. Cardiac function in congenital hypothyroidism: impairment and response to L-T4 therapy. *Pediatr Cardiol* 1991;12:28-32.
21. Ladenson PW, Goldenheim PD, Ridgway EC. Rapid pituitary and peripheral tissue responses to intravenous L-triiodothyronine in hypothyroidism. *J Clin Endocrinol Metab* 1983;56:1252-9.
22. Barlow CF, Priebe CJ, Mulliken JB, et al. Spastic diplegia as a complication of interferon Alfa-2a treatment of hemangiomas of infancy. *J Pediatr* 1998;132:527-30.
23. Deb G, Jenkner A, Donfrancesco A. Spastic diplegia and interferon. *J Pediatr* 1999;134:382.
24. Worle H, Maass E, Kohler B, Treuner J. Interferon alpha-2a therapy in haemangiomas of infancy: spastic diplegia as a severe complication. *Eur J Pediatr* 1999;158:344.