

Management of Orbital Subperiosteal Abscess in Children

Reza Rahbar, DMD, MD; Caroline D. Robson, MD; Robert A. Petersen, MD; James DiCanzio, MS; Kristina W. Rosbe, MD; Trevor J. McGill, MD; Gerald B. Healy, MD

Objectives: To present guidelines for the management of an orbital subperiosteal abscess (SPA) in children and to assess the efficacy and safety of transnasal endoscopic drainage of an orbital SPA.

Setting: Tertiary care children's hospital.

Patients: Nineteen patients treated for an SPA between July 1997 and December 1999. The age of the patients ranged from 17 months to 14 years (mean, 6 years). The male-female ratio was 10:9. Treatment modalities included transnasal endoscopic drainage (n=11), external drainage (n=3), and intravenous antibiotics alone (n=5).

Results: Bilateral pansinusitis was the most common cause. All patients received an initial trial of intrave-

nous antibiotics. Based on the Fisher exact test, no statistically significant differences were detected for age, sex, presence of gaze restriction, and radiographic findings. Based on multiple logistic regression, degree of proptosis was the only significant multivariate predictor of surgery ($P=.003$). The estimated probability of surgery was 6% when there was no proptosis, and 92% for 2 mm of proptosis. The location of the SPA determined the route of surgical drainage. Eleven patients with a medially based SPA underwent drainage via the transnasal endoscopic approach, and 3 with a superior SPA underwent drainage externally. The external approach was associated with a longer hospital stay (median, 7 days) than either the endoscopic or the intravenous antibiotic approach (median, 5 days).

Arch Otolaryngol Head Neck Surg. 2001;127:281-286

ACUTE SINUSITIS of the ethmoid and maxillary complex is the most frequent cause of a subperiosteal abscess (SPA). The incidence of an SPA in orbital infections is about 15% in children. The close anatomic relation of the orbit to the paranasal sinuses predisposes to the contiguous spread of infection through the ophthalmic venous system, which anastomoses freely with the facial, pterygoid, and cranial venous system. Retrograde spread of infection can lead to complications such as endophthalmitis, cavernous sinus thrombosis, meningitis, cerebritis, brain abscess, or death.¹⁻³ In the preantibiotic era, 20% of patients with periorbital cellulitis had permanent loss of vision, and 17% died from central nervous system complications.⁴ Today, despite antimicrobial and surgical management, 15% to 30% of patients with an SPA develop various visual sequelae.⁵

Treatment of an SPA remains controversial. The role of an initial therapeutic trial of intravenous (IV) antibiotics and

the timing and methods of surgical drainage are not well established. This report presents some guidelines for the diagnosis and treatment of an SPA based on clinical, ophthalmologic, and radiographic findings, and evaluates the efficacy and safety of endoscopic drainage of an orbital SPA.

RESULTS

PATIENTS

Nineteen patients were included in this study. The age range was 3 to 11 years (mean, 7.3 years) for the external drainage group, 2 to 11 years (mean, 5.4 years) for the IV antibiotics group, and 17 months to 14 years (mean, 5.8 years) for the endoscopic drainage group. The male-female ratio was 10:9 (**Table 1**). The most common clinical presentations were upper respiratory tract infection, fever, and eye swelling. There was no significant medical history in any patient, and immunizations were up-to-date in all.

From the Departments of Otolaryngology and Communication Disorders (Drs Rahbar, Rosbe, McGill, and Healy), Radiology (Dr Robson), Ophthalmology (Dr Petersen), and Clinical Research (Mr DiCanzio), The Children's Hospital, Boston, Mass; and the Departments of Otolaryngology and Laryngology (Drs Rahbar, Rosbe, McGill, and Healy), Radiology (Dr Robson), and Ophthalmology (Dr Petersen), Harvard Medical School, Boston.

PATIENTS AND METHODS

Nineteen patients with clinical and radiographic evidence of an orbital SPA secondary to sinusitis were treated at The Children's Hospital, Boston, Mass, between July 1997 and December 1999. All patients underwent a complete head and neck examination by the otolaryngology and ophthalmology services. The results of a computed tomographic (CT) scan were reviewed for all patients. All patients received an initial trial of IV antibiotics. Five patients were treated with IV antibiotics alone. Fourteen patients underwent surgical drainage: 3 via an external approach and 11 via transnasal endoscopic drainage of the SPA.

Endoscopic drainage was performed under general anesthesia. The nasal cavity was packed with oxymetazoline hydrochloride-soaked cotton for several minutes, and 0.5% lidocaine with 1:200000 epinephrine was used for local anesthesia. The middle turbinate was medialized, and the uncinate process was removed. A middle meatus maxillary antrostomy and complete ethmoidectomy were performed. The lamina papyracea was identified, and a Freer elevator was used to make an opening in the inferior aspect of the bone. The opening was enlarged to permit drainage of the SPA, and appropriate cultures were obtained. The nasal cavity was irrigated with copious amounts of isotonic sodium chloride solution and then coated with a water-soluble antibiotic ointment. No packing was used.

The variables analyzed included age, sex, clinical presentation, ophthalmologic manifestation, imaging findings, treatment modality, length of the hospital stay, complications, and microbiological specimens collected.

Patients requiring surgical intervention (by either procedure) were compared with those whose abscesses resolved with IV antibiotics based on sex, age, and clinical manifestations. Because of the small number of patients studied, we used nonparametric statistical methods for all comparisons. The Fisher exact test was used to evaluate differences in the distribution of sex, presence or absence of gaze restriction, and radiographic findings of (1) orbital fat involvement, (2) degree of rim enhancement (RE) of the SPA, and (3) number of ocular muscles enhanced. Patients' age, abscess volume, and degree of proptosis were compared with the Wilcoxon rank sum test. Length of the hospital stay associated with each type of intervention was compared using the Kruskal-Wallis test.⁶ A multiple stepwise logistic regression analysis⁷ was performed to identify the variables independently predictive of surgical intervention and to generate theoretical probability curves. For all statistical tests, results were considered significant if $P < .05$ (2-tailed). Data analysis was performed using SAS statistical software, version 6.12 (SAS Institute Inc, Cary, NC).

OPHTHALMOLOGIC EXAMINATION

All patients were examined by the ophthalmology service for (1) degree of periorbital or eyelid edema and erythema, (2) gaze restriction, (3) degree of proptosis, (4)

visual acuity, and (5) fundoscopic examination. All data were reviewed and interpreted by a single ophthalmologist (R.A.P.). All patients presented with marked eyelid edema and erythema, and were divided into those with complete eye closure and those with partial eye closure. Gaze restriction was noted in 10 of 11 patients in the endoscopic drainage group, 2 of 3 in the external drainage group, and 2 of 5 in the IV antibiotics group. All patients who underwent surgical drainage had proptosis, ranging from 2 to 5 mm (mean, 2.7 mm) for the endoscopic drainage group and 1 to 4 mm (mean, 2.3 mm) for the external drainage group. Only 1 patient from the IV antibiotics group had proptosis (2 mm). Visual acuity was normal in all patients. The fundoscopic examination revealed mildly dilated retinal vessels in only 2 patients from the endoscopic drainage group.

IMAGING FINDINGS

The CT images were reviewed by a single neuroradiologist (C.D.R.) blinded to the treatment modality. The CT scan was reviewed for (1) number and location of sinuses involved; (2) location, size, and RE of the SPA; (3) radiographic evidence of orbital fat and muscle changes; and (4) anatomical abnormality of the sinuses and adjacent structures (**Figure 1**).

Bilateral pansinusitis was the most common presentation. It was noted in 8 of 11 patients in the endoscopic drainage group, 2 of 3 in the external drainage group, and 4 of 5 in the IV antibiotics group. All other patients had involvement of more than 2 sinuses ipsilateral to the SPA. Maxillary and ethmoid sinuses were involved in all patients (Table 1).

The location of the SPA was described based on the medial axis of the orbit on coronal and axial images. Medial SPA was the most common location, noted in 10 of 11 patients in the endoscopic drainage group and in all 5 patients in the IV antibiotics group. One patient from the endoscopic drainage group presented with an inferior-medial SPA. Three patients presented with a superior-medial SPA. An estimated volume of the SPA (superior-inferior \times transverse \times anterior-posterior dimension) was recorded based on the largest superior-inferior, transverse, and anterior-posterior dimension on the axial and coronal CT images (**Table 2**).

The contralateral medial rectus muscle was used as a point of reference for describing the degree of radiographic RE of the SPA (1 indicates less; 2, equal; and 3, more). All patients showed RE equal to or greater than that of the medial rectus muscle, except for 3 from the IV antibiotics group, 1 from the external drainage group, and 2 from the endoscopic drainage group, who showed RE less than that of the medial rectus muscle. All patients showed orbital fat enhancement on CT, except 2 from the IV antibiotics group and 1 from the external drainage group.

Swelling and enhancement of at least 2 extraocular muscles were noted in all patients. Medial rectus, superior oblique, and superior rectus muscles were most commonly involved (Table 1). No specific anatomical abnormalities predisposing the patients to an SPA were noted.

Table 1. Characteristics of the Patients Studied*

Patient No./ Sex/Age, y	Hospital Stay, d	Follow-up, mo	Ophthalmologic Finding			Radiographic Finding			
			Eyelid	Gaze Restriction	Proptosis, mm	Sinuses Involved	Rim Enhancement†	Orbital Fat	Extraocular Muscle
IV Antibiotics Group									
1/M/3	5	27	CEC	R	0	B (M, E, and S) and FND	2	Yes	SO, SR, and MR
2/M/11	2	17	PEC	R	2	B (M, E, S, and F)	1	No	SO, SR, and MR
3/F/5	6	14	CEC	NL	0	B (M, E, and S) and FND	1	No	MR
4/M/2	5	14	CEC	NL	0	B (M, E, and S) and FND	1	Yes	MR and SO
5/M/6	5	29	CEC	NL	0	U (M, E, S, and F)	2	Yes	SO, SR, and MR
External Drainage Group									
6/M/8	7	14	CEC	R	4	U (M, E, S, and F)	2	Yes	SO, SR, and MR
7/F/11	14	30	PEC	R	2	B (M, E, and F)	1	Yes	SO and LR
8/M/3	7	24	PEC	NL	1	B (M, E, and S) and FND	2	No	SO and LR
Endoscopic Drainage Group									
9/F/11‡	5	13	CEC	R	4	U (M and E)	2	Yes	SO, SR, and MR
10/F/14	4	17	PEC	R	5	U (M, E, S, and F)	2	Yes	SO, MR, and IR
11/M/5	6	15	CEC	R	3	U (M, E, S, and F)	3	Yes	SO, MR, and IR
12/F/9	6	29	PEC	R	4	B (M and E)	3	Yes	SO, MR, IR, and SR
13/F/1.4‡	6	18	CEC	R	2	B (M, E, and S)	1	Yes	SR, IR, and MR
14/M/1.8	7	18	CEC	R	2	B (M, E, and S)	2	Yes	MR, SR, SO, and IR
15/F/2.4	3	12	CEC	R	2	B (M, E, and S) and FND	2	Yes	MR, SO, and SR
16/M/3	6	30	PEC	NL	2	B (M, E, and S)	2	Yes	SO, IR, MR, and LR
17/F/5	3	12	CEC	R	2	B (M, E, and S) and FND	1	Yes	MR, SO, SR, and IR
18/M/7	5	17	CEC	R	2	B (M, E, S, and F)	2	Yes	MR and SR
19/F/5	5	17	PEC	R	2	B (M, E, S, and F)	3	Yes	MR and IR

*Vision and fundi were normal in all patients. IV indicates intravenous; CEC, complete eye closure; R, restricted; B, bilateral; M, maxillary; E, ethmoid; S, sphenoid; FND, frontal not developed; SO, superior oblique; SR, superior rectus; MR, medial rectus; PEC, partial eye closure; F, frontal; NL, normal; U, unilateral; LR, lateral rectus; and IR, inferior rectus.

†A 1 indicates rim enhancement less than that of the medial rectus muscle; 2, equal to that of the medial rectus muscle; and 3, more than that of the medial rectus muscle.

‡This patient experienced dilation of retinal vessels.

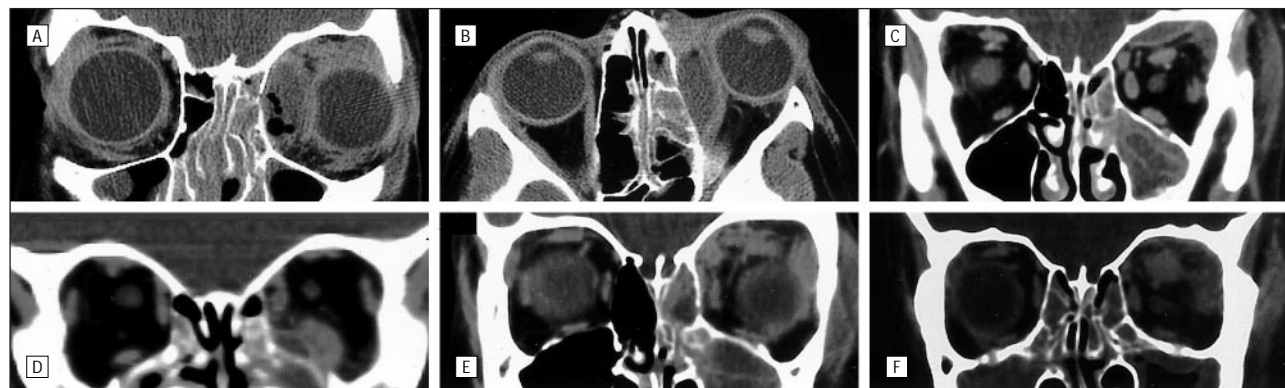

Figure 1. A, Coronal view of a medial SPA. B, Axial view of a medial SPA. C, Coronal view of a superior SPA. D, Coronal view of an inferior-medial SPA. E and F, Orbital fat and muscle enhancement. SPA indicates subperiosteal abscess.

TREATMENT

All patients received IV antibiotics and oxymetazoline nasal drops as the initial treatment. Visual examinations were performed twice daily by the ophthalmology service. Five patients responded well to IV antibiotics alone within the first 24 to 36 hours: 4 received a combination of ampicillin sodium and sulbactam sodium (Unasyn), and 1 received a combination of oxacillin sodium and cefotaxime sodium. The length of the hospital stay ranged from 2 to 6 days (mean, 5 days) for this group. All 5 patients were discharged home from the hospital with a prescription to take a combination

of amoxicillin and clavulanate potassium (Augmentin) for an average of 14 days. The other 14 patients received IV antibiotics (ampicillin sodium-sulbactam sodium or clindamycin) for 1 to 5 days (mean, 2 days) before surgical drainage. The principle indication for surgery was worsening of ophthalmologic examination results. Three patients with a superior SPA underwent external incision and drainage. The length of the hospital stay ranged from 7 to 14 days (mean, 9 days) for the external drainage group. One patient was discharged home from the hospital with a 1-week prescription of oral clindamycin, and 2 were discharged with a 10-day prescription of amoxicillin-clavulanate potassium.

Table 2. Measurement of SPAs*

Group	Dimension, mm†			Mean, mm‡
	Superior-Inferior	Transverse	Anterior-Posterior	
Endoscopic drainage	7-22	3-12	12-35	13, 6, and 23
External drainage	7-12	4-23	6-22	10, 14, and 16
IV antibiotics	4-14	2-15	10-24	9, 5, and 16

*SPA indicates subperiosteal abscess; IV, intravenous.

†Data are given as the range.

‡Data are given for the superior-inferior, transverse, and anterior-posterior dimensions, respectively.

Table 3. Demographic and Clinical Characteristics of Patients Successfully Treated With IV Antibiotics and Those Requiring Surgical Intervention*

Variable	IV Antibiotics Group (n = 5)	Surgery Group (n = 14)	P
Sex			
Male	1	8	.30
Female	4	6	
Gaze restriction			
Normal	3	2	.08
Restricted	2	12	
Fat involvement			
No	2	1	.16
Yes	3	13	
Rim enhancement			
1	3	3	.38
2	2	8	
3	0	3	
No. of muscles involved			
1	1	0	.32
2	1	4	
3	3	6	
4	0	4	
Age, median (range), y	5 (2-11)	5 (1.4-14)	.85
Volume, median (range), mm ³	600 (160-1008)	1452 (240-9240)	.04
Proptosis, median (range), mm	0 (0-2)	2 (1-5)	.004

*IV indicates intravenous.

Eleven patients underwent transnasal endoscopic drainage for a medially based SPA. Two of these patients required a second endoscopic procedure because of worsening of ophthalmologic examination results; this examination was performed 24 to 48 hours after the initial surgery. One patient had persistence of a purulent collection within the posterior ethmoid and orbital subperiosteal area. A second patient had a collection of antibiotic ointment, with an organized clot obstructing the surgical opening of lamina papyracea and the ethmoid cavity. Both patients showed improvement within 24 hours after the second procedure. The length of the hospital stay ranged from 3 to 7 days (mean, 5 days) for the endoscopic drainage group. All patients were discharged home from the hospital with a prescription to take amoxicillin-clavulanate potassium for an average of 10 days.

Purulent drainage was noted in 9 of 11 patients in the endoscopic drainage group and in all 3 patients in

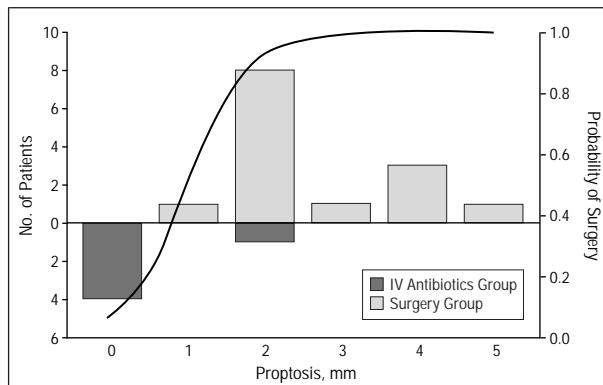


Figure 2. Frequency distribution (left axis) with respect to proptosis for patients successfully treated with intravenous (IV) antibiotics alone and those requiring surgical intervention. The theoretical curve showing the relation between the probability of surgery (right axis) and the degree of proptosis was derived from the logistic regression equation (slope, 2.55; intercept, -2.67; $P = .003$).

the external drainage group. Two patients in the endoscopic drainage group had serosanguineous drainage. Cultures grew combinations of streptococcus, staphylococcus, and *Haemophilus influenzae*. No anaerobic organisms were detected.

STATISTICAL RESULTS

The demographic and clinical characteristics of the surgical and nonsurgical patients are summarized in **Table 3**. No statistically significant differences were detected for sex, age, presence of gaze restriction, radiographic evidence of orbital fat involvement, degree of RE, or number of ocular muscles affected ($P \geq .08$ for all). Patients requiring surgical intervention tended to have a higher degree of proptosis and larger abscess volumes than did those whose abscesses resolved with IV antibiotics alone. However, results from the stepwise multiple logistic regression indicated that proptosis was the only significant multivariate predictor of surgical intervention (odds ratio, 12.9; $P = .003$). Since patients with larger abscesses also tended to have a higher degree of proptosis, the addition of abscess volume did not improve the predictive value of the model. Using the logistic regression equation, we can estimate the probability of surgery given the degree of proptosis. As illustrated in **Figure 2**, the estimated probability of surgery is approximately 6% when there is no proptosis (0 mm) and increases to 92% for a proptosis of 2 mm. Of the 2 types of surgical intervention, external excision was associated with a longer hospital stay (median, 7 days; range, 7-14 days) than either transnasal endoscopy (median, 5 days; range, 3-7 days) or IV antibiotics (median, 5 days; range, 2-6 days) ($P = .03$).

COMMENT

Orbital infection encompasses a wide range of causative factors: bacterial septicemia, penetrating injury, or secondary to skin infection. Sinusitis remains the most common cause of an acute orbital infection. Chandler et al⁴ proposed a classification system based on the extension

of the disease process ranging from periseptal cellulitis to cavernous sinus thrombosis. Orbital involvement is due to direct extension of infection through a natural bony dehiscence, local thrombophlebitis, or thromboemboli along the valveless venous system. This condition can affect all age groups, but is generally more frequent in the pediatric population.⁸

The management of an "acute orbit" depends on the cause and severity of infection. The typical presentation for preseptal cellulitis is inflammation of the eyelid, without proptosis or restriction of gaze. Orbital involvement could present as chemosis, proptosis, restriction of gaze, and visual changes. The distinction between preseptal cellulitis and orbital involvement is important, and cannot be made with clinical examination alone. Delay in treatment can result in blindness in up to 10% of patients with an SPA.⁹

The advent and evolution of orbital imaging techniques in the past 2 decades have enhanced the diagnosis of an SPA. The CT scan depicts a localized and homogeneous elevation of the periorbit adjacent to opacified sinuses. The classic CT appearance of an SPA is a convex low-density lesion with an enhancing rim next to the medial orbital wall. The presence of low density or air within the area is suggestive of abscess formation. There is no consensus as to the use of a CT scan as part of the initial workup. Some authors¹⁰ believe that imaging is not necessary for preseptal inflammation when there is no proptosis or gaze restriction. Some¹¹ also advocate an initial trial of IV antibiotics in cases suggestive of an SPA before obtaining a CT scan.

The most common presentation of an SPA in our series was periorbital swelling and erythema, which in isolation are physical findings that represent nonspecific inflammation common to preseptal and postseptal causes. We have presented 3 cases of an SPA manifesting with periorbital cellulitis, without any proptosis, restriction of gaze, or vision changes. Because of the aggressive nature of an SPA and the need for close monitoring of vision, we believe it is prudent to obtain a CT scan even if the only presentation is preseptal cellulitis, to further evaluate the status of the orbit. However, the role of a serial CT scan for evaluation of an SPA is controversial. There is evidence that the size of the SPA may increase during the first few days of IV antibiotic treatment regardless of the ultimate response to treatment.¹²

The treatment of an orbital SPA is controversial. Some authors¹³⁻¹⁵ advocate an initial trial of IV antibiotics despite radiographic evidence of an SPA. Others¹⁶⁻¹⁸ believe the presence of an SPA to be an absolute indication for immediate surgical drainage of the abscess and the infected sinuses. Even with appropriate treatment, there is a significant complication rate of 20% and a visual loss of 14% to 33%.¹⁹⁻²¹ The mechanism of visual loss is thought to be secondary to elevation of intraorbital pressure caused by the mass effect of the abscess, resulting in retinal ischemia due to central artery occlusion or thrombophlebitis along the valveless orbital veins. Visual loss may also occur because of optic neuritis caused by extension of infection.

We have described 19 patients with an SPA. Five patients responded well to conservative management.

Only patients with a superiorly based SPA underwent drainage externally. Eleven patients with a medial or a medial-inferior SPA underwent drainage through a transnasal endoscopic approach. Two patients from the endoscopic drainage group required a second endoscopic procedure. Patients were followed up for an average of 20 months, and no other complications were noted. There were no statistically significant differences between groups for sex, age, presence or absence of gaze restriction, and radiographic findings. The only significant multivariate predictor of surgical intervention was the degree of proptosis.

In patients with normal vision, a trial of IV antibiotics is reasonable only when careful monitoring of vision is possible. There is no consensus as to the proper frequency of visual examinations during initial medical management. Assessment of visual acuity ranging from every 2 hours to twice daily is recommended during the initial medical management of an SPA.²² Based on our data, the possibility of the need for surgical drainage based on the degree of proptosis should also be considered. According to our logistic model, patients presenting with proptosis of 2 and 3 mm had an estimated 92% and 99% chance of requiring surgical drainage, respectively. Therefore, it appears that in patients with proptosis greater than 2 mm, delay in surgical drainage would prolong the hospital stay and recovery periods.

Because of the potential for loss of vision and the devastating morbidity associated with an SPA, we recommend immediate surgical drainage when there is (1) impairment of vision, (2) worsening of the visual examination results (periorbital erythema or edema, proptosis, and restriction of gaze), (3) any sign of systemic manifestation or complication, (4) an inability to perform a reliable and serial ophthalmologic examination, (5) an immunocompromised patient, and (6) a lack of response to an initial trial of appropriate IV antibiotics. In our series, no patient required immediate surgical drainage. The duration of the initial IV antibiotic treatment should be individualized based on the serial ophthalmologic examination results. External drainage of an SPA and ethmoidectomy through a Lynch incision has been the traditional approach. With advances in sinonasal surgery, transnasal endoscopic drainage of SPAs has been popularized, as it reduces the necessity for an external incision and facilitates drainage of sinuses.^{23,24}

CONCLUSIONS

Prompt diagnosis and appropriate management of an SPA are essential to avoid serious and life-threatening complications. An individualized therapeutic approach should be based on a team decision involving the pediatrician, ophthalmologist, radiologist, and otolaryngologist. An initial trial of IV antibiotics is only appropriate when the visual acuity is normal and close monitoring is possible. Based on our experience, an orbital SPA can be successfully and safely managed by a transnasal endoscopic approach in selected patients. Methods of surgical drainage should be based on the location of the abscess and, most important, the experience of the otolaryngologist.

Accepted for publication August 11, 2000.

Presented at the American Society of Pediatric Otolaryngology, Orlando, Fla, May 17-19, 2000.

Corresponding author and reprints: Reza Rahbar, DMD, MD, Department of Otolaryngology and Communication Disorders, The Children's Hospital, 300 Longwood Ave, Boston, MA 02115 (e-mail: rahbar@a1.tch.harvard.edu).

REFERENCES

1. Davis JP, Stearns MP. Orbital complications of sinusitis: avoid delays in diagnosis. *Postgrad Med J*. 1994;70:108-110.
2. Eustis HS, Armstrong DC, Buncic JR, et al. Staging of orbital cellulitis in children: computerized tomography characteristics and treatment guidelines. *J Pediatr Ophthalmol Strabismus*. 1986;23:246-251.
3. Lesser A, Stern GA. Preseptal and orbital cellulitis. *Infect Dis Clin North Am*. 1992; 6:933-952.
4. Chandler JR, Langenbrunner DJ, Stevens ER. The pathogenesis of orbital complications in acute sinusitis. *Laryngoscope*. 1970;80:1414-1428.
5. Osguthorpe JD, Hochman M. Inflammatory sinus disease affecting the orbit. *Otolaryngol Clin North Am*. 1993;26:657-671.
6. Hollander M, Wolf DA. *Nonparametric Statistical Methods*. New York, NY: John Wiley & Sons Inc; 1973.
7. Hosmer DW, Lemeshow S. *Applied Logistic Regression*. New York, NY: John Wiley & Sons Inc; 1989.
8. Schramm VL Jr, Curtin HD, Kennerdell JS. Evaluation of orbital cellulitis and results of treatment. *Laryngoscope*. 1982;92:732-738.
9. Patt BS, Manning SC. Blindness resulting from orbital complications of sinusitis. *Otolaryngol Head Neck Surg*. 1991;104:789-795.
10. Jones DB, Steinkuller PG. Strategies for the initial management of acute preseptal and orbital cellulitis. *Trans Am Ophthalmol Soc*. 1988;86:94-108.
11. Uzcategui N, Warman R, Smith A, Howard CW. Clinical practice guidelines for the management of orbital cellulitis. *J Pediatr Ophthalmol Strabismus*. 1998;35:73-79.
12. Harris GJ. Subperiosteal abscess of the orbit: computed tomography and the clinical course. *Ophthalm Plast Reconstr Surg*. 1996;12:1-8.
13. Towbin R, Han BK, Kaufman RA, Burke M. Postseptal cellulitis: CT in diagnosis and management. *Radiology*. 1986;158:735-737.
14. Goodwin WJ, Weinshall M, Chandler JR. The role of high resolution computerized tomography in the evaluation of orbital cellulitis. *Laryngoscope*. 1982;92: 728-731.
15. Souliere CR Jr, Antoine GA, Martin MP, Blumberg AI, Isaacson G. Selective non-surgical management of subperiosteal abscess of the orbit: computerized tomography and clinical course as indication for surgical drainage. *Int J Pediatr Otorhinolaryngol*. 1990;19:109-119.
16. Teele DW. Management of the child with a red and swollen eye. *Pediatr Infect Dis*. 1983;2:258-262.
17. Fairbanks DNF, Milmo GJ. Complications and sequelae: an otolaryngologist's perspective. *Pediatr Infect Dis*. 1985;4:575-578.
18. Hirst LW, Thomas JV, Green WR. Periocular infections. In: Mandell GC, Douglas RG Jr, Bennett JE, eds. *Principles and Practice of Infectious Disease*. 2nd ed. New York, NY: John Wiley & Sons Inc; 1985:770.
19. Hornblass A, Herschorn BJ, Stern K, Grimes C. Orbital abscess. *Surv Ophthalmol*. 1984;29:169-178.
20. Harris GJ. Subperiosteal abscess of the orbit. *Arch Ophthalmol*. 1983;101:751-757.
21. Spires JR, Smith RJH. Bacterial infections of the orbital and periorbital soft tissue in children. *Laryngoscope*. 1986;96:763-767.
22. Rubin SE, Rubin LG, Zito J, Goldstein MN, Eng C. Medical management of orbital subperiosteal abscess in children. *J Pediatr Ophthalmol Strabismus*. 1989; 26:21-26.
23. Manning SC. Endoscopic management of medial subperiosteal orbital abscess. *Arch Otolaryngol Head Neck Surg*. 1993;119:789-792.
24. Pereira KD, Mitchell RB, Younis RT, Lazar RH. Management of medial subperiosteal abscess of the orbit in children: a 5 year experience. *Int J Pediatr Otorhinolaryngol*. 1997;38:247-254.